



# The Clinical Results of Endoscopic Dacryocystorhinostomy

M Hafit Gur<sup>1</sup>, Koksall Yuca<sup>2</sup>, Adnan Cinal<sup>3</sup>, A Faruk Kiroglu<sup>4</sup>, Y Kursad Varsak<sup>2</sup>, Hakan Cankaya<sup>4</sup>

## ABSTRACT

Epiphora is a clinical case characterised with the liquefaction of the eyes as the tears can not reach to the nasal cavity because of an obstruction in the nasolacrimal system. Endoscopic dacryocystorhinostomy (EDCR) can be used primary or as a revision surgery to treat chronic dacryocystitis. The aim of this study is to evaluate the results of EDCR operation. In the study, clinical results of 80 patients after the EDCR operation have been evaluated. Bilaterally EDCR was applied to 12 of the female patients and 92 eyes were examined in total including 82 female patient eyes and 10 male patient eyes. Bicanalicular silicon tube was inserted to 72 of the patients and T tube was inserted to 5 of the patients, in 15 patients only anastomosis of the lacrimal sac to the nasal passage was performed. Patients were observed for minimum 6 and maximum 36 months. A total 80 patient underwent surgery. 70 of the patients were female and 10 of them were male. The average age was 38 years. The most common complaint epiphora detected in all patients. 48.9% of surgery was on right side. 8 (8.7%) of 92 eyes had synechia between the lateral nasal wall and the middle concha lateral surface and 16 (17.4%) of them had granulation tissues around the ostium. 8 (8.7%) eyes underwent the revision EDCR and 5 (5.4%) of them benefited. Average stay duration of the silicon tube and its standart deviation were calculated as  $4.64 \pm 1.271$  (3-6) months. Complete success rate and partial success rate was determined 78.3% and 15.2% respectively. In conclusion, EDCR is a well tolerated a valid alternative operation with low incidence of complications and has a high general success rate. Furthermore, endoscopic surgery may also have a benefit of preserving the lacrimal pump system and leaving no surgical scar.

**Key words:** Epiphora, dacryocystorhinostomy, endoscopy

## Endoskopik Dakriyosistorinostominin Klinik Sonuçları

### ÖZET

Epifora, gözyaşının lakrimal sistemdeki tıkanıklıktan dolayı nazal kaviteye geçememesi ile gelişen gözde yaşarma ile karakterize bir durumdur. Endoskopik dakriyosistorinostomi (EDSR) kronik dakriyosistit tedavisinde primer veya revizyon cerrahisi olarak uygulanabilen bir yöntemdir. Bu çalışmanın amacı EDSR operasyonunun sonuçlarını değerlendirmektir. Bu çalışmada EDSR operasyonu uygulanan 80 hastanın klinik sonuçları değerlendirilmiştir. 12 kadına bilateral EDSR olmak üzere 82 bayan, 10 erkek gözüne cerrahi uygulandı. 72 hastaya bikanaliküler silikon tüp, 5 hastaya T tüp ve 15 hastaya sadece lakrimal kese nazal pasaj anastomozu yapıldı. Hastalar minimum 6 hafta, maksimum 36 hafta olmak üzere gözlemlendi. 70 kadın, 10 erkek olmak üzere 80 hastaya cerrahi uygulandı. Ortalama yaş 38 idi. En sık şikayet epifora olup bütün hastalarda epifora mevcuttu. Operasyon %48.9 sağ tarafa uygulandı. Cerrahi uygulanan 92 gözden 8 (%8.7)'inde lateral nazal duvar ve orta konka lateral nazal duvarı arasında sineşi, 16 (%17.4) hastada ostium etrafında granülasyon dokusu gelişti, hastaların 8'ine (%8.7) revizyon EDSR uygulandı. Bunlardan 5 tanesi operasyondan fayda gördü. Silikon tüplerin ortalama kalış süresi ve standart sapması  $4.64 \pm 1.271$  (3-6) hafta olarak hesaplandı. Komplet ve parsiyel başarı oranları sırası ile 78.3 % ve 15.2 % olarak belirlendi. Sonuç olarak EDSR düşük komplikasyon insidansı, yüksek genel başarı oranı ile iyi tolere edilebilen alternatif bir operasyon tekniğidir. Ayrıca endoskopik cerrahi lakrimal pompa sistemini koruyan ve cerrahi skar bırakmayan bir yöntemdir.

**Key words:** Epifora, dakriyosistorinostomi, endoskopi

<sup>1</sup>Ent Specialist in Bitlis State Hospital, <sup>2</sup>N. E. University Meram Medical Faculty Department Of Otorhinolaryngology, <sup>3</sup>Yüzüncü Yıl University Medical Faculty Department Of Ophtalmology, <sup>4</sup>Yüzüncü Yıl University Medical Faculty Department Of Otorhinolaryngology

**Correspondence:** Koksall Yuca, MD. Professor  
N.E. University Meram Medical Faculty  
Department of Otorhinolaryngology  
Head and Neck Surgery,  
42080 Konya / Turkey  
E-mail: koksalyuca@yahoo.com

Received: 16.01.2012, Accepted: 02.03.2012

## INTRODUCTION

Acquired nasolacrimal duct obstruction is the most common cause of the epiphora (1). Obstructions in the lacrimal system can occur at any point on the pathway of the lacrimal drainage system and this situation is classified as pre-sac (joint canaliculus), related to the sac and post-sac with surgical purposes (2). The standart treatment method applied to the acquired nasolacrimal duct obstruction is generally external DCR operation. The failure rate of the external DCR is stated to be 5-15 % in many publications (3). With the start of the use of endoscopic devices frequently for the diagnosis and treatment of the endonasal pathologies recently, EDCR is applied more frequently and accurately. Nowadays, EDCR is used as primary or generally with the aim of revision after the open technique. This method has started to charm surgeons as it provides operation easiness and has a lower morbidity rate. It can also have a success rate near to that of external method (3,4). The first modern external DCR operation was realised by Toti in 1904 (2). In parallel with the medical-technological developments of the last decade, an extraordinary increase is being observed in the EDCR practices (4,5). In this study, we have evaluated the success rates of the cases on which bicanalicular silicon application was performed and those on which bicanalicular silicon application was not performed as well as the success rates of the cases to which T-tube was inserted to the lacrimal sac in company with the literature. All these cases had the acquired nasolacrimal duct obstruction and had underwent EDCR.

## MATERIALS AND METHODS

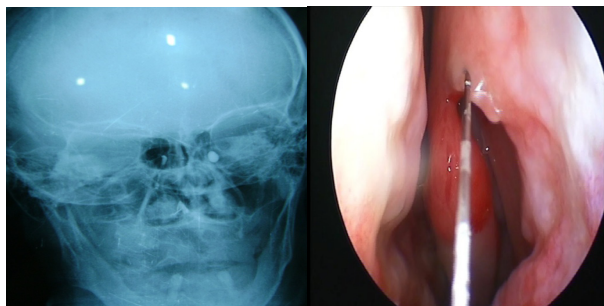
In this study, patients who resorted to the Eye Polyclinic of the Medicine Faculty Hospital of Van Yüzüncü Yıl University with the compliant of epiphora between January 2006-June 2009 and were diagnosed with cronic dacryocystitis at the end of the ophtalmologic examination and lipiodol dacryocystography and underwent a EDCR operation by being directed to the otorhinolaryngology polyclinic were evaluated. Post-operation success rates of 80 patients who came for the control examinations were assessed. 70 of the patients were female and 10 of them were male. Bilaterally EDCR was applied to 12 of the female patients. 92 eyes were examined in total including 82 female patient eyes and 10 male patient eyes. Bicanalicular silicon tube was inserted to 60 of the patients and T tube was inserted to 5 of

the patients by performing incision to the sac, but in 15 patients only the anastomosis of the lacrimal sac to the nasal passage was performed. Biopsy was conducted on the lacrimal sac wall of 20 patients whose complaints had been continuing for 60 and 120 months and also culture was taken from 10 patients who had an obvious pus during the lacrimal sac incision. Patients were observed for minimum 6 and maximum 36 months.

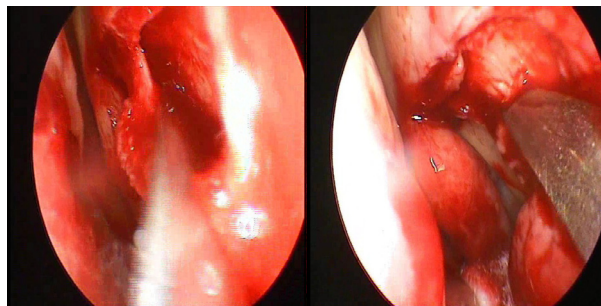
All the patients were evaluated according to the Munk criteria for the epiphora grades prior to the EDCR. All the patients had grade 5 epiphora. During the follow-ups of the patients, the epiphora grades were also evaluated according to the Munk criteria. Punctum lavages of all the patients were evaluated to be blocked. The patients' anterior-posterior and lateral dacryocystographies were taken and also their sac and lacrimal pathways were examined by giving them lipiodol through the punctum. In our study, evaluation through the lipiodol dacryocystography prior to EDCR has been applied to all patients. It was observed that the sacs of all the patients filled perfectly and their integrity was not distorted. In all patients, obstruction was in the region following the sac.

Local anesthesia was preferred in the EDCR operations of all the patients. Mucosal openness was used by performing lavage and the punctums were dilated by the ophtalmolog. Passing the visitec 5012 silikon tube through the upper and lower punctums, free ends were tied within the nasal cavity. By the way, the patients who had middle concha hypertrophy and septum deviation were intervened limitedly and these pathologies were also eliminated. The operation was terminated by placing a small tampon to the nasal cavity. The patients were discharged in the 1st day following the operation with an eye drop including tropical antibiotic, nasal decongestant, sistemic antibiotic and analgesic. The physiological serum and nasal irrigation was recommended to them until the control. The patients were examined 7 days, 1 month, 3 months, 6 months and 9 months after the operation. Postoperative radiological examination was not conducted. The tube was removed without the necessity of anesthesia by cutting the upper end and pulling it from the nasal pathway.

The elimination of the epiphora in the patients under the normal circumstances, the absence of a recurring infection and the fluid given with the punctum lavage to reach to the nasal cavity were evaluated as a com-



**Figure 1.** In the left, the lacrimal sac is observed and local anesthesia is applied to the adhesion point of the left middle concha



**Figure 2.** Mucoperiosteal flap is elevated, frontal notch of the lacrimal bone and the maxillary bone is removed by means of a hammer guj

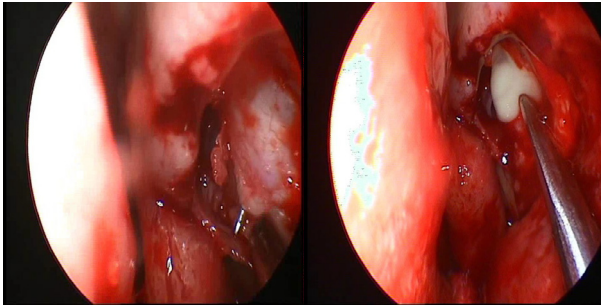
plete success. The success was accepted to be partial when the patients had an epiphora less severe than the situation prior to the operation and the punctum lavage passed to the nose partially through the ostium. As for surgical failure, it was described as the blockage of the ostium or the presence of a persistent and recurring epiphora in the patient.

## RESULTS

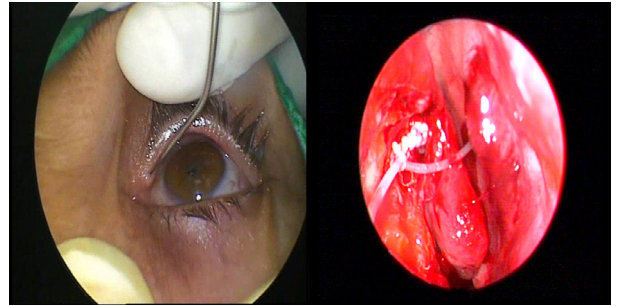
In total, 92 eyes were examined in the study. The number of the eyes belonging to the female patients was 82 (89.1%) and to the male was 10 (10.9%). While the average age of the female patients and its standard deviation were  $39.48 \pm 13.09$  (17-70) and the average age of the male patients and its standard deviation were  $31.20 \pm 6.861$  (24-42), the average age of all the patients included in the study and its standard deviation were calculated as  $38.58 \pm 13.54$  (17-70). Of all the patients included in the study, the average duration of the complaints and its standard deviation were calculated as  $31.39 \pm 24.41$  (4-120) months, the average duration of follow-ups and its standard deviation were calculated as  $15.52 \pm 7.452$  (6-36) months. In the patients to whom bicanalicular silicon tube was applied, the average stay duration of the silicon tube and its standard deviation were calculated as  $4.64 \pm 1.271$  (3 - 6) months and the average duration of the follow-ups and its standard deviation in the patients whose silicon tube was removed were calculated as  $11.56 \pm 7.077$  (5 -32) months.

Of all 92 eyes included in the study, bicanalicular silicon tube was applied to 72 (78.3%) of them and T tube application was performed to the lacrimal sacs of 5 (5.4%)

eyes. In 15 (16.3%) patients, only the anastomosis of the lacrimal sac to the nasal passage was performed. From 92 eyes, right EDCR was applied to 45 of them (48.9%), left EDCR was applied to 47 of them (51.1%). 30 (32.6%) of the patients included in the study had septum deviation and 5 (5.4%) of them had middle concha hypertrophy. Septoplasty was applied to 25 (27.2%) of these and the middle concha bullosa resection was applied to 5 (5.4%). All 92 eyes included in the study had the epiphora, 32 (34.8%) of them had crusts around them, 16 (17.4%) of them had rash and pruritus and 10 (10.9%) eyes had acute dacryocystitis when they resorted to the hospital. Culture was taken from 10 (10.9%) patients who had an obvious pus from the sac during the EDCR and the biopsy specimen was taken for the pathological examination from 20 patients whose complaints had been continuing for between 60 and 120 months. As the result of the culture that was taken, it was observed that *Streptococcus pneumoniae* multiplied in 4 patients, *Staphylococcus aureus* in 2 patients and *Staphylococcus epidermidis* in 2 patients from Gram (+) microorganisms. As for Gram (-) microorganisms, the multiplication of *Pseudomonas aeruginosa* was detected in 2 patients. All the pathological specimens were reported as chronic active inflammations. During the endoscopic nasal examination conducted in the course of the patients' follow-ups, 8 (8.7%) of 92 eyes included in the study had synechia between the lateral nasal wall and the middle concha lateral surface and 16 (17.4%) of them had granulation tissues around the ostium. 8 (8.7%) of 92 eyes which were included in the study and continued to have the same complaints underwent the revision EDCR and 5 (5.4%) of them benefited from the revision EDCR. Intraoperative punctum perforation de-



**Figure 3.** It is ensured that the sac constitutes a notch to the window that was opened by putting pressure on the sac with a finger from the outside and a vertical incision is conducted on the sac



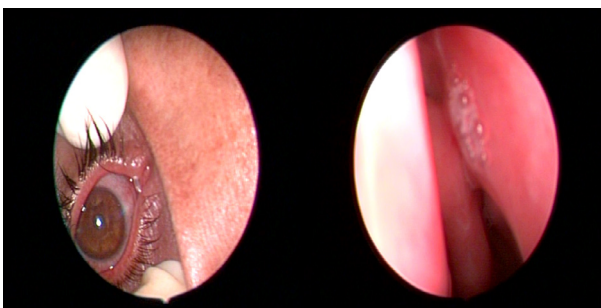
**Figure 4.** Punctums are dilated and free ends are tied within the nasal cavity by passing the silicon tube through the upper and lower punctums

veloped in 3 eyes, orbital emphysema resulting from the blow of the nose in the postoperative period occurred in 1 eye and periorbital oedema and ecchymosis developed in 5 patient eyes. While complete success was yielded in 72 of ( 78.3%) 92 patients included in the study, partial success was yielded in 14 (15.2%) of them (Grade 2 epiphora was present in 12 eyes and Grade 3 epiphora was present in 2 eyes). Of 72 eyes on which complete success was ensured, bicanalicular silicon tube was applied to 57 (79.2%) eyes and T tube application to the lacrimal sac was performed in 5 (6.9%) eyes. As for 10 patients, only the anastomosis of their lacrimal sacs to the nasal passage was performed. In 6 patients whose punctum lavages were blocked, it was observed during the endoscopic nasal examination that there were intense granulation tissues around the ostium and there was synechia between the middle concha and the lateral nasal wall.

While granulation tissues were detected around the ostium in 10 patients to whom applications were performed with a partial success, the cause of the partial failure of 4 cases could not be explained completely.

#### DISCUSSION

The traditional treatment of the nasolacrimal obstructions is generally performed by ophthalmologists and includes the traditional external dacryocystorhinostomy. Dacryocystorhinostomy can be conducted through external or intranasal methods and both methods has its own specific advantages and disadvantages. Endonasal approach was first introduced by Caldwell (15) in 1893, later on modified by West (16) and Hall (17). EDCR has such advantages as minimal morbidity, a small amount of intraoperative hemorrhage, a short operation time, the ability of the orbicularis oculi muscle to continue its sac pump function, a better cosmetic appearance (7). As EDCR provides a smaller openness, it has some disadvantages such as; more frequent recurrence and the need to use devices like endoscope or microscope. Its another disadvantage is that it is more difficult to learn (8,9). Great advantages of the external DCR are that a complete control over the anatomy is possible, it allows the removal of the bones of a sufficient number, anastomosis can be conducted between the nasal mucosa and the lacrimal sac. In addition to these, in the presence of any pathologic membrane extending through the sac from the canalicul, the lesion can be detected and incised and the possible unexpected pathologies of the sac can be detected (10).



**Figure 5.** The silicon tube passed through the lower and upper punctums is seen and it is observed that tears of the patient whose bicanalicular silicon tube is removed drain from the ostium



Dacryocystitis is a pathology that is frequently seen in the middle-aged women. The average age of the patients with dacryocystitis is reported to be between 41.5 and 63 in various studies (26-29). Female patients have constituted the 89.1% of all the cases included in our study. We have calculated the average age of all the patients as 38.58.

Önerci and his colleagues (18) put forward various factors that can be the causes of the failures in the wake of their study conducted on 158 patients; wrong localization of the lacrimal sac, development of granulation tissue around the tubes, bone lamellae that are left, insufficient excision of the medial wall of the sac and an adhesion between the middle concha and lateral nasal wall have been counted as the most common causes. The ostium's close proximity to the middle concha and damage of the mucosa that is either on the concha or is on the adjacent septum appear in front of us as the causes of obstruction by leading to adhesions in the postoperative period (21). As for our study, the most common causes of the failures were the composition of the nasal synechia and granulation tissue at the proportion of 30% and granulation tissues only around the ostium at the proportion of 50%. But the cause of failure in 20% of all the cases could not be found out exactly.

Local inflammatory reaction depending on the silicon tube intubation, small mucosa and punctum polyps, punctum erosion and cornea complications have been reported (19,20). The most common complications of EDCR can be counted as the blockage of the ostium with the progressive scarring, ostium's adhesion with middle concha and septum, growth of granulation within the nasal ostium and lacrimal sac diverticulum whose drainage could not be performed after the operation (22). As for less common complications, they are the intraoperative or postoperative hemorrhage. This hemorrhage can result from both the mucosa erosion and the adhesion point of the middle concha. Other complications are punctal erosion depending on the damage of the silicon tube, canalicular obstruction, orbital fat herniation, orbital and subcutaneous emphysema, formation of conjunctival fistula and retrobulbar hemorrhage (23,24). During the follow-ups conducted in our study, we have observed that the punctum perforation was present in 3 (3.3%) patients. This value is pretty close to the ratio of 4.35% found and reported in another study of the literature (20). Keeping the silicon tube more tight than it has to be while it is tied within the nose may have

caused this complication. Other complications observed in our study were periorbital oedema and ecchymosis in 5 (5.4%) patients, periorbital emphysema in 1 (1.1%) patient and the most common complications were granulation tissues around the ostium and nasal synechia detected in 24 (26.1%) patients.

In literature, the most common symptom detected in cases with acquired nasolacrimal duct obstruction is the complaint of epiphora and has a ratio between 77.5% and 85% (29-33). In a study composed of forty-one cases, while epiphora can be the only symptom during the application it has been reported that epiphora is accompanied by acute dacryocystitis or chronic dacryocystitis at the proportion of 70% (34). The other symptoms have been specified as the acute dacryocystitis alone (11.2%) or the chronic dacryocystitis alone (11.2%) (30). The symptoms that we detected in the patients in our study were the formation of crusts round the eyes (34.8%), rash and pruritus (17.4%) as well as the epiphora observed in all the cases. Moreover, we have found out that the symptoms of our patients were accompanied by the acute dacryocystitis and chronic dacryocystitis respectively at the proportions of 10.9% and 89.1%.

While Kuchar and his colleagues (6) isolated 49.3% gram (+) microorganisms from the materials that they collected from the cultures of the patients with dacryostenosis, they also isolated gram (-) microorganisms at the proportion of 50.7%. They detected most frequently the *Streptococcus pneumoniae* from the gram (+) microorganisms. As for the gram (-) microorganisms, they encountered most frequently with the *Haemophilus influenzae* and secondly *Pseudomonas aeruginosa*. In our study, as a result of the cultures taken from 10 patients who had an obvious pus during the lacrimal sac incision, it is observed that *Streptococcus pneumoniae* multiplied in 4 patients, *Staphylococcus aureus* in 2 patients and *Staphylococcus epidermidis* in 2 patients from gram (+) microorganisms. We have also detected the multiplication of *Pseudomonas aeruginosa* from the gram (-) microorganisms in 2 patients. Önerci and his colleagues (18) have emphasized that the silicon tubes must be removed before the 3th month as a longer intubation may cause the formation of granulation tissues. Kong (8) has stated that the removal of the silicon tubes before the 8th week impedes the formation of granulation tissues. However, Boush (35) has declared that the longer the tube has remained, the more the success rate has increased. In our study, we kept the silicon tubes

in their places for minimum 3 and maximum 6 months. The silicon tubes remained in their places for an average of 4.64 months. We have discovered that in our series, granulation tissues resulting from silicon tubes appeared at most after the 2 th month. Within the scope of our study, we applied punctum lavage to all the cases prior to the operation and found out that lavage was blocked in all the cases. Furthermore, we had all the cases in our series undergo lipiodol dacryocystography and observed that the contrast agent remained in the sac and did not pass to the nasal passage.

The studies in the literature state that the dacryocystography is the traditional radiological method in evaluating the cases with acquired nasolacrimal duct obstruction. As the contrast agent that is given disappears immediately during the normal nasolacrimal lavage while sitting in a vertical position, visibility of this contrast in late films demonstrates that there exists an obstruction in the passage (36). In the study of Önerci and his colleagues (18), the success rate of EDCR has been stated as 94.4% when performed by the experienced surgeons and as 58% when performed by inexperienced surgeons. Çokkeser (37) has reported the success rate of EDCR that is conducted with hammer and microosteotomy as 88.2 %. But Akiner (11) has reported its success rate as 83.3 % in his study. Whittet and his colleagues (7) states a success rate of 94.7% in a case group composed of 19 patients. The success rate in Weidenbecher and his colleagues' (12) case group composed of 56 patients is 86%. Eventually in our study, our complete success rate was 78.3%, the partial success rate was 15.2% and our general success rate was 93.5%. We have found out that our general success rate is compatible to the studies included in the literature.

Dacryocystitis is a pathology which affects frequently the middle-aged women. In accordance with the literature, the majority of the cases was also composed of middle-aged women in our study. Epiphora was the most important complaint detected in all cases. The most common postoperative complication and the most frequent cause of failure were the synechia between the lateral nasal wall and middle concha and granulation tissues around the ostium. Tubes of the patients to whom the silicon tube application was performed kept in their places for an average 4.64 months. Long term silicon tube intubation can lead to granulation tissues. In our study, we detected the formation of granulation tissues around the ostium after 2 th month at most.

In our study, our complete success rate was 78.3%, the partial success rate was 15.2% and our general success rate was 93.5%. We have found out that our general success rate is compatible to the studies included in the literature. At the end of this study, we have agreed upon that the EDCR is a functional operation that can be tolerated well by the patients, is preferred thanks to its cosmetic advantage as it does not cause incision scars visible from the outside, has a minimal trauma potential, protects the medial palpebral ligament and the lacrimal pump mechanism, allows the treatment of intranasal pathologies simultaneously if needed and has a high success rate.

#### REFERENCES

1. Linberg JV, Mc Cormick SA. Primary acquired nasolacrimal duct obstruction; a clinicopathologic report and biopsy technique. *Ophthalmology* 1986;93:1055-63.
2. MacEven CJ, Young JDH, Barras CW, Ram B, White PS. Value of nasal endoscopy and probing in the diagnosis and management of children with congenital epiphora. *Br J Ophthalmol* 2001;85:314-8.
3. Çinal A, Kutluhan A, Yaşar T, Şimşek Ş, Kırış M, İçli M. The comparison of the internal and external methods in the surgical treatment of chronic dacryocystitis. *T Oft Gaz* 1999;29:292-7.
4. Küpper DS, Demarco RC, Resende R, et al. Endoscopic nasal dacryocystorhinostomy: result and advantages over the external approach. *Braz J Otorhinolaryngol* 2005;71:356-60
5. Knijnik D. Endonasal dacryocystorhinostomy in children. *Braz J Otorhinolaryngol* 2005;71:726-8.
6. Kuchar A, Lukas J, Steinkogler FJ. Bacteriology and antibiotic therapy in congenital nasolacrimal duct obstruction. *Acta Ophthalmol Scand* 2000;78:694-8.
7. Whittet HB, Shun-shin GA, Awdry P. Functional endoscopic transnasal dacryocystorhinostomy. *Eye* 1993;7:545-9.
8. Kong YT, Kim TI, Byung WK. A report of 131 cases of endoscopic laser lacrimal surgery. *Ophthalmology* 1994;101:1793-800.
9. Bartley GB. Acquired lacrimal drainage obstruction: an etiologic classification system, case reports and review of literature. *Ophthalmol Plast Reconstr Surg* 1992;8:237-42.
10. Yung MW, Hardman\_Lea S. Analysis of the results of surgical endoscopic dacryocystorhinostomy: effect of the level of obstruction. *Br J Ophthalmol* 2002; 86: 792-4.
11. Akiner M, Anadolu Y, Aktürk T, Uğurlubaş SH, Zilelioğlu G. Endoscopic transnasal dacryocystorhinostomy. *J Otolaryngol Head Neck Surg* 1996;4:44-8.
12. Weidenbecher M, Hosemann W, Buhr W; Endoscopic endonasal dacryocystorhinostomy; Results in 56 patients. *Ann Otol Rhinol Laryngol* 1994;103:363-7.

13. Önerci M, Orhan M. Endoscopic intranasal dacryocystorhinostomy. *J Otolaryngol Head Neck Surg* 1993;2(3):219-22.
14. Mclahlan DL, Shannon GM, Flanagan JC: Results of dacryocystorhinostomy. Analysis of reoperations. *Ophthalmic Surg* 1980;11:427-30.
15. Bengner R, Forer M. Endonasal dacryocystorhinostomy primary and secondary. *Aust N Z J Ophthalmol* 1993;21(3):157-9.
16. Rice DH. Endoscopic intranasal dacryocystorhinostomy in four patients. *Arch Otolaryngol Head Neck Surg* 1990;116(9):1061.
17. Mcdonogh M. Endoscopic Transnasal Dacryocystorhinostomy. Endoscopic transnasal dacryocystorhinostomy. Results in 21 patients. *S Afr J Surg* 1992;30(3):107-10.
18. Önerci M, Orhan M, Öğretmenoğlu O, Irkeç M. Long-term results and reasons for failure of intranasal Endoscopic dacryocystorhinostomy. *Acta Otolaryngol* 2000;120(2):319-22.
19. Sodhi PK, Pandey RM, Malik KPS. Experience with bicanalicular intubation of the lacrimal drainage apparatus combined with conventional external dacryocystorhinostomy. *J Craniomaxillofac Surg* 2003;31:187-90
20. Argın A, Duman S, Örnek F. The role of the silicon intubation in dacryocystorhinostomy (Turkish). *J Mersin Univ Med Faculty* 2001;3:281-4
21. Metson R. The Endoscopic Approach for Revision Dacryocystorhinostomy. *Laryngoscope* 1990;100:1344-7.
22. Watkins LM, Janfaza P, Rubin PA. The evolution of endonasal dacryocystorhinostomy. *Surg Ophthalmol* 2003;48:73-84.
23. Ünlü HH, Toprak B, Aslan A, Güler C. Comparison of surgical outcomes in primary endoscopic dacryocystorhinostomy with and without silicone intubation. *Ann Otol Rhinol Laryngol* 2002;111: 704-9.
24. Şan İ, Gürler B. Endoscopic dacryocystorhinostomy: 'Operative problems in the initial cases'. *Turk Arch Otolaryngol* 2002;40:258-63
25. Munk PL, Lin DT, Morris DC. Epiphora: treatment by means of dacryocystorhinostomy with balloon dilation of the nasolacrimal drainage apparatus. *Radiology* 1990;177(13):687-90.
26. Luchtenberg M, Kuhli C, du Mesnil de Rochemont R, Yan B, Ohrloff C, Berkefeld J. Three-dimensional rotational dacryocystography for imaging of the lacrimal draining system and adjacent anatomical structures. *Ophthalmologica* 2005;219(3):136-41.
27. Yoshii M. External Dacryocystorhinostomy: outcomes after the introduction of two new forceps and transnasal endoscopy. *Med Sci Monit* 2004;10(3):39-42.
28. Yazici B, Yazici Z. Final nasolacrimal ostium after external dacryocystorhinostomy. *Arch Ophthalmol* 2003;121(1):76-80.
29. Boboridis KG, Bunce C, Rose GE. Outcome of external dacryocystorhinostomy combined with membranectomy of a distal canalicular obstruction. *Am J Ophthalmol* 2005;139(6):1051-5.
30. Kashkouli MB, Parvareh M, Modarreszadeh M, Hashemi M, Beigi B. Factors affecting the success of external dacryocystorhinostomy. *Orbit* 2003; 22(4):247-55.
31. Groessl SA, Sires BS, Bradley N. An anatomical basis for primary acquired nasolacrimal duct obstruction. *Arch Ophthalmol* 1997;115:71-4
32. Örnek F, Duman S, Kasım A. The causes of the lacrimal drainage system obstructions that can not be monitored with a contrast agent and the surgical approach. *T Klin Ophthalmology* 1996;5(3):206-8.
33. Cuthbertson FM, Webber S. Assessment of functional nasolacrimal duct obstruction survey of ophthalmologists in the southwest. *Eye* 2004;18(1):20-3.
34. Becker BB. Dacryocystorhinostomy without flaps. *Ophthalmic Surg* 1988;19(6):419-27.
35. Boush GA, Bradley NL, Dortzbach RK. Results of endonasal laser-assisted dacryocystorhinostomy. *Ophthalmology* 1994;101:955-59 .
36. Wearne M, Pitts J, Frank J, and Rose G. Comparison of dacryocystography and lacrimal scintigraphy in the diagnosis of functional nasolacrimal duct obstruction. *Br J Ophthalmol* 1999;83(9):1032-5.
37. Çokkeser Y, Evreklioğlu C, Er H. Comparative external versus endoscopic dacryocystorhinostomy: Results in 115 patients (130 eyes). *Otolaryngol Head Neck Surg* 2000;123(4): 488-91.