

# Takayasu's Arteritis and Mitral Stenosis

Goutam Datta, Biswakesh Majumder, Dipankar Mukherjee

## ABSTRACT

A young female presented with NYHA class III symptoms, absent lower limb and left radial pulses. Echocardiography showed severe mitral stenosis and left atrial clot. Abdominal aorta was cut off distal to renal artery with collaterals to lower limb vessels. Left subclavian artery was totally occluded distal to vertebral artery. She had HLA DR3.

**Key words:** Takayasu's arteritis, mitral stenosis, abdominal aorta coarctation

## Takayasu Arteriti ve Mitral Darlık

### ÖZET

NYHA III semptomları olan ve alt ekstremiteler ile birlikte sol radyal nabız yokluğu olan genç bir bayanı sunduk. Ekokardiyografi sol atriyumda pıhtı ve şiddetli mitral darlığını gösterdi. Abdominal aorta alt ekstremiteler damarlarına kollateraller ile renal arterin distalinde kesiliyordu. Sol subklavyan arter total olarak vertebral arterin distalinde tama yakın tıkalıydı. Hastanın HLA DR3'ü pozitif idi.

**Anahtar kelimeler:** Takayasu arteriti, mitral darlık, abdominal aorta koarktasyonu

## INTRODUCTION

Takayasu's arteritis is a form of chronic idiopathic large vessel vasculitis involving the aorta and its major branches. It mostly affects young females in their 2<sup>nd</sup> and 3<sup>rd</sup> decades. It is commonly found in the Asian countries though cases has increasingly been recognized from Africa, Eastern Europe and South America. Estimated incidence rate is 2.6 cases per million persons per year. It evolves through two phases namely early prepulseless or active phase and late pulseless or ischaemic phase with symptoms secondary to aortic or arterial stenosis. Coarctation of the abdominal aorta is a rare anomaly. Although congenital and acquired causes have been described, acquired stenosis of the abdominal aorta caused by Takayasu's arteritis seems to be more common than congenital hypoplasia of the aorta. The aetiology of Takayasu's arteritis is not known. Rheumatic fever is one of the causes previously postulated but this has never been confirmed. Association between Takayasu's arteritis and valvular heart disease

has not been clearly described in literature. We have recently come across a patient with Takayasu's arteritis presenting as coarctation of the abdominal aorta who also had mitral stenosis (1-4).

## CASE

A 35 years old lady presented with shortness of breath. She was having NYHA class III symptoms and paraparesis. She had history of lower limb claudication for five years. Clinical examination revealed absent lower limb and left radial pulses. The first heart sound was accentuated and the second heart sound physiologically split with loud pulmonary component. There was an opening snap followed by long diastolic murmur at the apex. Abdominal and left subclavian bruit were also present. Haematological and biochemical parameters were within normal limits. Echocardiography showed severe mitral stenosis (mitral valve area. 9cm<sup>2</sup>) and clot in left atrium. There was mainly mitral valve thickening with

Institute of postgraduate medical education and research Calcutta, India

Received: 25.04.2011, Accepted: 01.12.2011

Correspondence: Goutam Datta

Institute of postgraduate medical education and research Calcutta, India

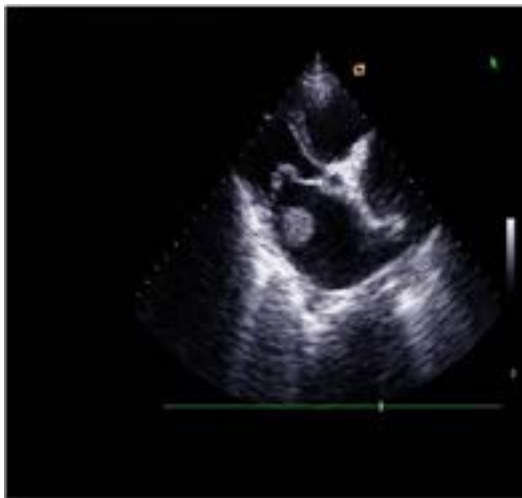


Figure 1. Mitral stenosis and clot in left atrium

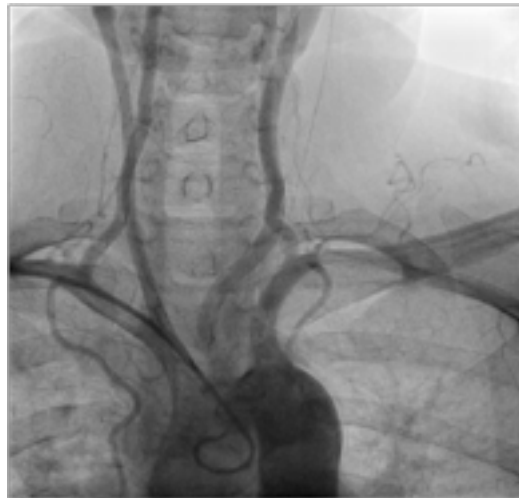

Figure 3. Totally occluded left subclavian artery

no subvalvular involvement. Aortic valve was morphologically normal. Aortogram through right radial route revealed that abdominal aorta was cut off distal to renal artery and there were collaterals to lower limb vessels. Left subclavian artery was totally occluded distal to vertebral artery. Nerve conduction velocities were severely reduced in lower limb. Computer tomography of spine was normal.

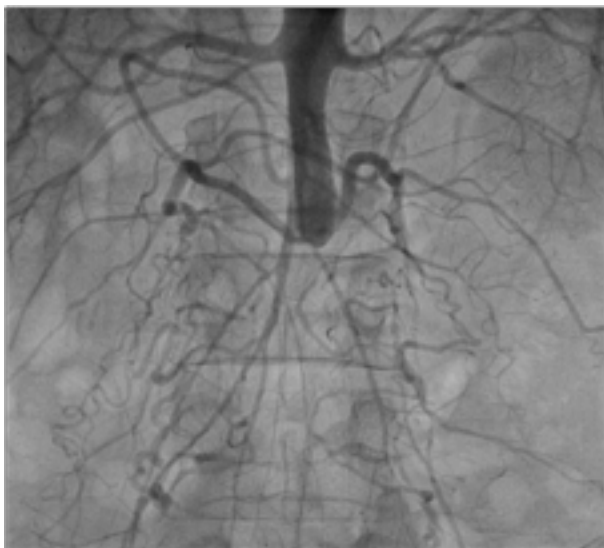


Figure 2. Abdominal aorta is cut off distal to renal artery with collaterals

## DISCUSSION

Takayasu, a Japanese ophthalmologist, reported the first case of aortoarteritis in 1908. Coarctation of the abdominal aorta is a rare anomaly. Although congenital and acquired causes have been described, acquired stenosis of the abdominal aorta caused by Takayasu's arteritis seems to be more common than congenital hypoplasia of the aorta. A new angiographic classification of Takayasu arteritis, as per Takayasu conference 1994 (1).

Type: Vessel involvement

Type I: Branches from the aortic arch

Type IIa: Ascending aorta, aortic arch and its branches

Type IIb: Ascending aorta, aortic arch and its branches, thoracic descending aorta

Type III: Thoracic descending aorta, abdominal aorta, and/or renal arteries

Type IV: Abdominal aorta and/or renal arteries

Type V Combined features of types IIb and IV

Association between Takayasu's arteritis and valvular heart disease is very rare. Initial cases were mild MS (mitral stenosis), mild MS/MR (mitral regurgitation) (2). AR (aortic regurgitation) may occur due to aortic root involvement. Doi et al reported a case of Takayasu's arteritis and mild mitral stenosis (3). Nikolic et al described a case of Takayasu's disease with aortic regurgi-

tation and mitral stenosis (4). Aetiology is unclear—most favoured is autoimmune mechanism. Tuberculosis, rheumatoid arthritis, rheumatic fever have also been postulated. Coarctation of the abdominal aorta in our patient is thought to be secondary to Takayasu's arteritis. Inflammatory signs such as elevated sedimentation rate and leukocytosis were absent in our patient. They are excellent indices for the activity of the disease, but may disappear over time and are significantly less frequent in older patients as the systemic phase of the disease resolves. It is possible that a number of these different antigenic stimuli could lead to the final pathologic changes. On the other hand, it may also be possible that organic changes of the mitral valve in our patient could result from Takayasu's arteritis itself. Our patient had experienced acute phase of Takayasu's arteritis at the age of 9 and majority of patients with Takayasu's arteritis experience an acute systemic phase characterized by symptoms such as fever, malaise, arthralgia, and skin manifestations, which at times may mimic rheumatic fever. Although it remains to be seen whether our case represents an etiological relation or just a casual association, present documentation of mitral stenosis in a patient with Takayasu's arteritis may raise two possibili-

ties: first, rheumatic fever (silent) may be in aetiologically related to Takayasu's arteritis. Secondly, Takayasu's arteritis may at times involve the mitral valve, as it occasionally involves the aortic valve. Takayasu's arteritis and severe mitral stenosis is extremely rare association. Our patient had HLA-DR3 which is associated with both rheumatic fever and Takayasu's arteritis.

## REFERENCES

1. *Moriwaki R, Noda M, Yajima M, et al. Clinical manifestations of Takayasu arteritis in India and Japan-new classification of angiographic findings. Angiology 1997;48:369-79*
2. *Almotarreb A, Alabsi M. Takayasu's arteritis and rheumatic heart disease. Heart Views 2004;5(1):24-5*
3. *Doi yi, Seo H, Hamashige M, Jin nouchi Y, Ozawa T. Takayasu's arteritis and mitral stenosis. Clin Cardiol 1998;11(2): 123-5*
4. *Nikolic J, Peclard M, Deleamont P, Chavaz P, Schifferli J, Bounameaux H. Takayasu's arteritis preceded by cardiac and cutaneous lesions. A case report. Vasa 1993;22(4)347-57*