

# Juvenile Granulosa Cell Tumor and High Blood Ca-125 Levels in Children with Pseudo-Meigs Syndrome

Ilhan Ciftci<sup>1</sup>, Mustafa Ozgur Pirgon<sup>2</sup>, Yasar Unlu<sup>3</sup>

## ABSTRACT

Ovarian tumors and cysts are rarely seen in children. They constitute 1-2% of solid tumors among children. Over tumors are categorized into three main groups: epithelial, embrionic, and sex cord-stromal tumors. Sex cord-stromal tumors arise from primordial cell cords that are located in the center of the ovary during embriological development. We have detected a patient who was diagnosed with a juvenile granulosa cell tumor (JGCT) at two years of age after presenting with excessive breast enlargement during the past month. She had a large mass in the abdomen, ascites, and marked pleural effusion in the right hemithorax. This association was Pseudo-Meigs syndrome. The association of JGCT and Pseudo-Meigs syndrome is a considerably rare event. Moreover, since the patient was the youngest among all previously reported cases in existing literature, our observations indicate that a juvenile granulosa cell tumor may occur at an early age. In conclusion, Pseudo-Meigs syndrome with JGCT shouldn't forget, even in young children.

**Key words:** Meigs syndrome, child, Ca-125, granulosa cell tumor

## Juvenile Granüloza Hücreli Tümörü ve Psödo Meig Sendromlu Çocukta Yüksek Kan Ca-125 Düzeyi

### ÖZET

Çocuklarda over kist ve tümörleri nadirdir. Yaklaşık olarak solit tümörlerin %1-2 kadarını oluşturur. Over tümörleri üç gruba ayrılır: epitelyal, embrionik ve sex kord stromal tumor. Sex kord stromal tümörler overin central parçasında primordial hücrelerden oluşur. Biz iki yaşında meme büyümesi şikayeti ile gelen juvenile granüloza hücreli tümörü(JGHT) olan olguyu tespit ettik. Olguda büyük intraabdominal kitle, asit ve sağ hemitoraksta pleval efüzyon mevcuttu. Bu birliktelik Pseudo-Meigs sendromu idi. JGHT ile beraber olan Pseudo-Meigs sendromu oldukça nadir görülmektedir. Bu kadar küçük yaşta literatürde bulunmamaktadır. Sonuç olarak küçük çocukta olsa JGHT ile Pseudo-Meigs sendromu birlikteliği unutulmamalıdır.

**Anahtar kelimeler:** Meig sendromu, çocuk, Ca-125, granüloza hücreli tümör

## INTRODUCTION

Ovarian tumors and cysts are rarely seen in children. They constitute 1-2% of solid tumors among children. They are categorized into three main groups: epithelial, germ cell, and sex cord-stromal tumors. Sex cord-stromal tumors originate from primordial cell cords that are located in the center of the ovary during embriological development (1). Juvenile granulosa cell tumor (JGCT) is the most common type of sex cord-stromal tumor.

While this tumor may be formed only by granulosa cells, it may contain varying amounts of theca cells and fibroblasts (2). Due to estrogen release, patients may clinically demonstrate gynecomastia, vaginal hemorrhage, premature pubarche, irregular menstruation, and precocious puberty. Moreover, clinical symptoms may be accompanied by pelvic or abdominal masses, ascites, and pleural effusion. Unilateral oophorectomy or salpingo-oophorectomy is the treatment of choice (3). We

<sup>1</sup>Department of Pediatric Surgery, Selcuk University, Medical Faculty, Konya, Turkey, <sup>2</sup>Department of Pediatric Endocrinology, Suleyman Demirel University, Medical Faculty, Isparta, Turkey, <sup>3</sup>Department of Pathology, Konya Training and Research Hospital, Konya, Turkey

Received: 25.12.2011, Accepted: 25.03.2013

Correspondence: Ilhan Ciftci, M.D., Selcuk Universitesi Tip Fakultesi, Cocuk Cerrahisi A. D. Konya, Turkey  
Tel: 00903322415000, Fax: 00903322412184  
E-mail: driciftci@yahoo.com

present a two-year-old female patient who was deemed a remarkable case due to the presence of a large mass in the abdomen, ascites, and a marked pleural effusion in the right hemithorax. The association of JGCT and pseudo-Meigs syndrome is a considerably rare event.

### CASE

A two-year-old female patient was presented with her family to the Pediatric Endocrinology Polyclinic at our hospital because, during the past month, she experienced excessive breast enlargement. The patient was of 13 kg weight (10 percentile) and 86 cm (25 percentile) in height. She had thelarche (Tanner stage III) and her abdomen was distended. A manual examination revealed a mobile mass that was 15 cm in size with a smooth and solid surface. It began in the upper abdomen and extended towards the pelvic region. It was impalpable over the lower border and predominantly localized within the left lower quadrant. Right inguinal hernia was determined (Figure 1). The carbohydrate antigen (CA) 125 value was 366 U/mL (normal range: 0-35 U/mL). The estradiol concentration was 602.5 pg/mL (normal range: 6.0-27 pg/mL). Ultrasonography of the abdomen demonstrated a mass lesion with cystic solid areas that was located over the abdominal midline, extending from epigastric region to pelvic region and showing a size of 12 x 7.5 cm at its largest. The pelvic region exhibited fluid, whereas right pleural area was

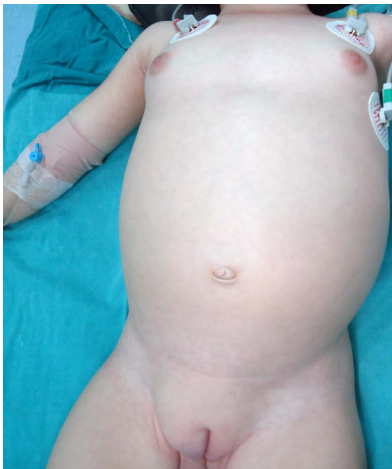

Figure 1. Mass began in the upper abdomen and extended towards the pelvic region.

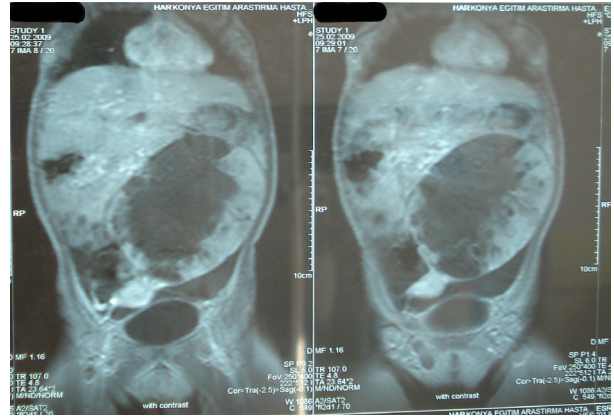
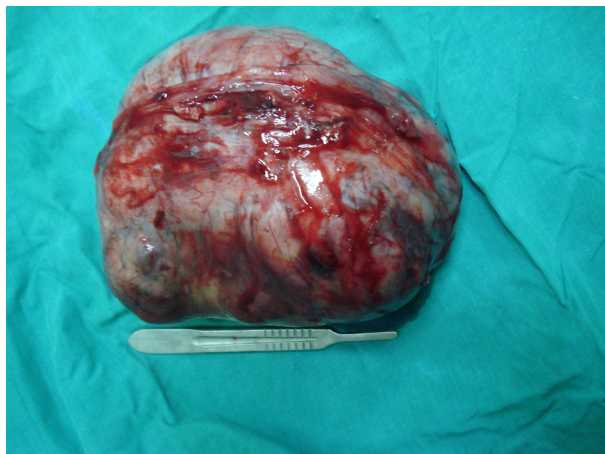


Figure 2. The mass was thought to originate from the left ovary.

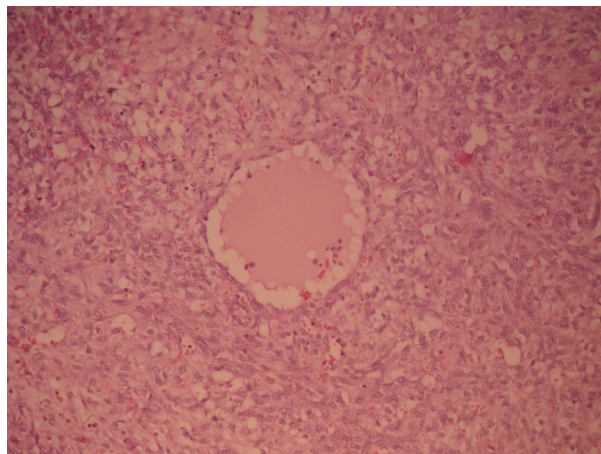
free of fluid. Intraabdominal free fluid was evident on her abdominal MRI image. Moreover, free fluid was also detected over the right lower thorax. In addition; there was a mass that demonstrated an intense peripheral contrast uptake and included necrotic areas. This mass was 13 x 10 x 8 cm in size. It completely occupied the abdominal midline and left hemiabdomen, while exhibiting hypointense areas on T1W and heterogeneous hyperintense areas on T2W images. The mass was thought to originate from the left ovary (Figure 2). The patient underwent an operation in which an abundant amount of ascites was aspirated. The 15-cm capsulated mass, which was showing adhesions with the omentum, was

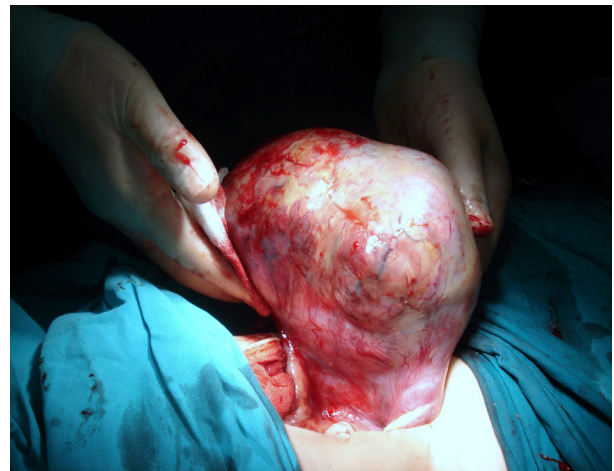

Figure 3. The 15 cm capsulated mass.



**Figure 4.** The left uterine cornu was removed along with the fallopian tube.



**Figure 5.** Created follicle-like structures that contained eosinophilic material in some areas

excised (Figure 3). It was observed to originate from the left ovary, which was within the tumoral mass, and the tumor was determined to be adhered to the left uterine cornu. Superficially, the left uterine cornu was removed along with the fallopian tube (Figure 4). Loculated ascites was aspirated. Liver, spleen, paraaortic areas, and the contralateral ovary were examined. They were found to be normal. A right inguinal hernia was repaired. Peritoneum, fascia, and skin were closed. The procedure was ended by thoracocentesis for inspection purposes.

An ovarian tissue of tumoral appearance and 17x16x15 cm size, which displayed cystic structures with a diameter of 5 cm at its largest point, was observed along with patchy hemorrhagic or mucoid pinkish-red areas. The sections revealed evidence that indicated that the tumor's development had completely destroyed the ovarian tissue. The mildly pleomorphic and hyperchromatic tumoral cells were observed to be oval-shaped with round nuclei and eosinophilic cytoplasm that formed solid islets over large areas or created follicle-like structures that contained eosinophilic material in some areas (Figure 5). No nuclear groove was seen. Vacuolations were notable in the cytoplasm of some of the cells. There were occasional theca cells and the mitosis in the tumoral cells was remarkable. The follow-ups did not reveal any problems. Hydrothorax disappeared after 1 month. The laboratory values for CA-125 and estradiol were 12 U/mL and 30 pg/ml at 1 month, respectively.

## DISCUSSION

Clinically, the triad of ovarian fibroma, ascites, and hydrothorax is defined as Meigs syndrome. Meigs syndrome was first defined by J. V. Meigs (4, 5). Pseudo-Meigs syndrome consists of pleural effusion, ascites, and a benign tumor of the ovary other than fibromas (6). Ascites and hydrothorax should be a collection of malignant fluid. However, it is difficult to establish an accurate diagnosis prior to the operation (7). Respiratory distress stems from a large tumoral mass that obstructs the respiratory airway or an excessive collection of pleural fluid (4). Our patient had abdominal distension without abdominal pain and pseudo-Meigs syndrome was observed. However; the patient had no respiratory problems despite the presence of a huge mass. The underlying mechanisms of ascites and hydrothorax development are not known. Various theories have been proposed. Ascites is suggested to arise from the direct edematous fluid secretion or an impaired lymphatic flow caused by tumoral tissue with a diameter that is larger than 10 cm (8). Additionally, intermittent torsioning of the tumor further increases the fluid collection, after which necrosis-related cystic formations may develop (4).

The mechanism of hydrothorax formation is believed to arise from a congenital defect in the right lymphatic duct and lymphatic ducts of the right crus of diaphragm (9). However, this does not appear to be a reasonable theory because the fluid collection resolves after the removal of the tumor. Therefore, the theory which

proposes that the fluid collection occurs as a result of certain agents released from the tumor tissue is more widely recognized (10). In some cases, hydrothorax development may reach stages in which severe respiratory failure arises and emergency intervention is required (11).

The CA-125 level is elevated in the combined presence of hydrothorax and ascites in cases with an ovarian tumor (12). Moreover, it is particularly elevated in cases of benign diseases in which peritoneal and pleural fluid collections are present. However, there is no study which indicates that an elevated CA-125 level can lead to hydrothorax or ascites. It is only a suggestion that hydrothorax or ascites might raise CA-125 levels (13).

Our case was a two-year-old female patient. Literature only cites a few cases in which a JGCT has occurred at such a young age (14-16); however, our review did not reveal any hydrothorax in those cases. In adults, pseudo-Meigs syndrome associated with JGCT has been reported (17-19). In children, pseudo-Meigs syndrome accompanied by a JGCT is a rare observation (20). We decided to present this case because of this patient's extremely young age appeared to be younger than any other cases that have been described in literature.

In conclusion, pseudo-Meigs syndrome with JGCT can be encountered, even in young children. Cytological analysis may be performed, but unless respiratory distress is present, it is unnecessary to perform an intervention in hydrothorax cases.

#### REFERENCES

1. Raafat F, Klys H, Rylance G. Juvenile granulosa cell tumor. *Pediatr Pathol* 1990;10(4):617-23.
2. Powell JL, Johnson NA, Bailey CL, Otis CN. Management of advanced juvenile granulosa cell tumor of the ovary. *Gynecol Oncol* 1993;48(1):119-123.
3. Vassal G, Flamant F, Caillaud JM, Demeocq F, Nihoul-Fekete C, Lemerle J. Juvenile granulosa cell tumor of the ovary in children: a clinical study of 15 cases. *J Clin Oncol* 1988;6(6):990-5.
4. Meigs JV, Cass JW. Fibroma of the ovary with ascites and hydrothorax. *Am J Obstet Gynecol* 1937;33:249-67.
5. Meigs JV. Fibroma of the ovary with ascites and hydrothorax: Meigs' syndrome. *Am J Obstet Gynecol* 1954; 67: 962-85.
6. Dunn JS Jr, Anderson CD, Method MW. Hydropic degenerating leiomyoma presenting as pseudo-Meigs syndrome with elevated CA 125. *Obstet Gynecol* 1998;92(4 Pt 2): 648-9
7. Chourmouzi D, Papadopoulou E, Drevelegas A. Magnetic resonance imaging findings in pseudo-Meigs' syndrome associated with a large uterine leiomyoma: a case report. *J Med Case Reports* 2010 28;4:120.
8. Bridgewater JA, Rustin GJS. Pseudo-Meigs' syndrome secondary to an ovarian germ cell tumor. *Gynecol Oncol* 1997;66:539-41.
9. Cotran RS, Kumar V, Collins T. The female genital tract. In: Cotran RS, Kumar V, Collins T, editors. *Robbins pathologic basis of disease*. Philadelphia7 WB Saunders Co; 1999. p. 1035-91.
10. Lin JY, Angel C, Sickel JZ. Meigs syndrome with elevated serum CA 125. *Obstet Gynecol* 1992;80:563-6.
11. Tae Soo Hahm, Ji Sun Ham, and Ji Yeong Kang. Unilateral massive hydrothorax in a gynecologic patient with pseudo-Meigs' syndrome. *Korean J Anesthesiol* 2010; 58(2): 202-6.
12. Jones III OW, Surwit EA. Meigs' syndrome and elevated CA 125. *Obstet Gynecol* 1989;73:520-1.
13. Timmerman D, Moerman P, Vergote I. Meigs' syndrome with elevated serum CA 125 levels: Two case reports and review of the literature. *Gynecol Oncol* 1995;59:405-8.
14. Leyva-Carmona M, Vázquez-López MA, Lendinez-Molinos F. Ovarian juvenile granulosa cell tumors in infants. *J Pediatr Hematol Oncol* 2009;31(4):304-6.
15. Capito C, Flechtner I, Thibaud E, et al. Neonatal bilateral ovarian sex cord stromal tumors. *Pediatr Blood Cancer* 2009;52(3):401-3.
16. Young RH, Dickersin GR, Scully RE. Juvenile granulosa cell tumor of the ovary. A clinicopathological analysis of 125 cases. *Am J Surg Pathol* 1984;8(8):575-96.
17. Kaur H, Bagga R, Saha SC, et al. Juvenile granulosa cell tumor of the ovary presenting with pleural effusion and ascites. *Int J Clin Oncol* 2009;14(1):78-81.
18. Papathanasiou K, Papageorgiou C, Tsonoglou D. A case of Meigs' syndrome with a gigantic granulosa ovarian tumor. *Clin Exp Obstet Gynecol* 1998;25(1-2):61-3.
19. Choi K, Lee HJ, Pae JC, et al. Ovarian granulosa cell tumor presenting as Meigs' syndrome with elevated CA125. *Korean J Intern Med* 2005;20(1):105-9.
20. Wolff AL, Ladd AP, Kumar M, Gunderman RB, Stevens J. Pseudo-Meigs syndrome secondary to ovarian germ cell tumor. *J Pediatr Surg* 2005;40(4):737-9.