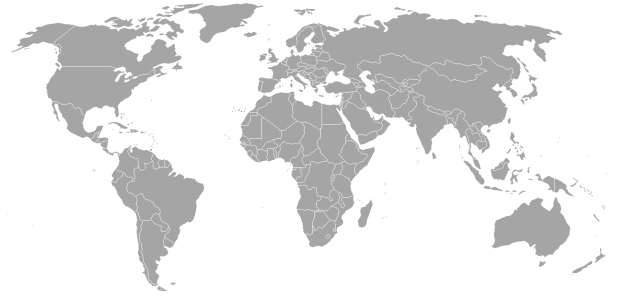


# Infectious Pericarditis



M Akif Büyükbese<sup>1</sup>, Hasan Uçmak<sup>2</sup>

## ABSTRACT

Mostly self-limited with an idiopathic or infectious etiology, pericarditis may be fatal in rare occasions. Thin layer surrounding myocardium is infected especially by viral organisms. Here, a recent Turkish and world literature will be reviewed and cases of Epstein Barr virus, H1N1 virus as well as tuberculosis microorganisms leading to pericarditis and even tamponade will be discussed. You will also find rare parasitic infestations presenting with pericardial effusion, constrictive and crystal pericarditis of infectious origin and read other rare metabolic associations such as myxedema and uremia.

**Key words:** Pericarditis, infectious pericarditis, infection

## Enfeksiyöz Perikardit

### ÖZET

Sıklıkla kendi kendini sınırlayabilen, nedeni belli olmayan ve enfeksiyöz nedenlerin etyolojide önde geldiği perikardit hastalığında nadir durumlarda ölüm görülebilir. Miyokardı çevreleyen ince zar özellikle viral organizmalar tarafından enfekte olmaktadır. Burada, yakın zamanda yayınlanan Türk ve dünya literatürüne göz atılacak ve Epstein Barr virüs, H1N1 virüs ve tüberküloz gibi perikardite ve hatta tamponada neden olabilen mikroorganizmalar tartışılacaktır. Enfeksiyon kaynağı olarak perikardiyal efüzyon, konstriktif ve kristal perikarditleri ile karşımıza çıkan nadir parazit enfestasyonlarını da keza bulabileceğimize ve miksödem ve üremi gibi metabolik olaylarla nadiren olan birlikteliklerini okuyacaksınız.

**Anahtar kelimeler:** Perikardit, enfeksiyöz perikardit, enfeksiyon

## INTRODUCTION

Pericardium anatomically is a thin layer surrounding and protecting the heart from outside damage. Inflammation of this serous layer will cause many clinical pictures such as arrhythmias and chest pain -that may need differential diagnosis with myocardial infarction-. Idiopathic (1) and then infectious are the most common reasons for pericarditis and below the latter will be discussed below.

### Viruses

Among children viruses are majority of infectious peri-

carditis (2,3). Coxsackie B virus, echovirus, and adenovirus are the most frequent pathogens associated with this condition, other viruses such as influenza, mumps, varicella (VZV), human immunodeficiency virus (HIV), and Epstein-Barr virus (EBV) can be the underlying causes of pericarditis, as well (2-4). Acute infectious pericarditis, pericarditis mostly may be caused by enterovirus family, in particular Coxsackieviruses. Although self-limited in case of the absence of immunodeficiency (5), EBV which belongs to Herpesviridae family does rarely cause pericarditis, although a young patient developing pericardial tamponade has been published (6). It is the cause of infectious mononucleo-

<sup>1</sup>KSU School of Medicine, Internal Medicine Department, Kahramanmaraş, <sup>2</sup>KSU School of Medicine, Infectious Disease Department, Kahramanmaraş

Received: 24.04.2012, Accepted: 15.08.2012

Correspondence: KSU School of Medicine, Internal Medicine Department, Kahramanmaraş, <sup>2</sup>KSU School of Medicine, Infectious Disease Department, Kahramanmaraş

sis and may be present with sore throat, lymphadenopathy, elevated liver enzymes, polymyalgia, fever, asthenia, hepatomegaly, splenomegaly....etc. Asymptomatic course may also be noted as well as pericarditis and myocarditis (7,8). A positive blood test of viral capsid antibody (VCA) IgM and EBV polymerase chain reaction (PCR) positivity of pericardial effusion help for a prompt diagnosis (6). Tamponade has also been reported with an offending agent like EBV, but especially in the elderly, and on the very rare occasions in a young patient without immunodeficiency condition (6).

An eight year old girl has been reported to have acute pericarditis with parvovirus B19 (PVB19) infection (9). This virus also had been responsible for adult pericarditis related heart failure (10). It may also cause fetal myocarditis, perimyocarditis (11). Specific IgM antibodies against the virus detected by ELISA and DNA analysis by PCR help for the diagnosis. Abrupt reductions in hemoglobin, hematocrit, erythroid mass, and reticulocyte values were thought to result from transient erythroblastopenia associated with PVB19 infection. It is also the cause of erythema infectiosum (fifth disease), in pediatric cases. Tumor markers had even been studied in patients with viral etiology and cancer patients (12). Carbohydrate antigens CA12-5 and CA 15-3 together with carcinoembryogenic antigen (CEA) had been compared and viral etiology pericarditis demonstrated only slight elevation during acute phase with diminishing levels after a mean of one year follow-up (12). Apart from this elevated CA-125 level in acute heart failure due to *Toxoplasma gondii* perimyocarditis had been also published (13).

### **H1N1 Virus**

Pericarditis and pericardial effusion have been occasionally associated with influenza A infections. Although common features of seasonal influenza A include fever, cough, sore throat, myalgia, pneumonia, asthma, and bronchitis, the most common manifestation of swine-origin influenza A is a respiratory tract infection (pneumonia; 40% of patients) owing to a report from United States (14). Swine-origin influenza A (H1N1) is caused by a new strain of the influenza virus. The disease had spread rapidly and was declared a pandemic in April, 2009. As of November 20th, 2009, H1N1 has infected 526,060 patients worldwide and killed 6,770 (15). A single case of fulminant myocarditis was found in a child infected with swine influenza A (16). This virus can af-

fect the infants. A 3-month-old boy with this novel influenza A (H1N1) infection complicated by pericardial effusion had been reported (17). The patient was treated with pericardial drainage, oseltamivir, and ibuprofen and then improved. Another case of myopericarditis - but this time fatal- presenting with cardiac tamponade in a previously healthy 11-year-old child had also been described (18). Report was from Italy and cardiac failure had been developed during the course. Findings suggest that cardiac tamponade and heart failure following myopericarditis in this young patient were due to direct tropism and damage caused by the 2009 H1N1 influenza virus. Pandemic H1N1 2009 influenza A virus sequences were identified in throat and myocardial tissues and pericardial fluid, suggesting damage of myocardial cells directly caused by the virus.

### **Bacterial pericarditis**

Viral pericarditis often present with fever and chest pain and less toxic profile comparing with bacterial pericarditis. Nevertheless, if myocarditis accompanies which usually does, then clinical view gets worsen (3). Although purulent pericarditis is a rare entity in the modern antibiotic era, it is also a devastating condition and has the possibility to mortality. Purulent pericarditis should be remembered as a life-threatening disease and bacterial origin. Even though tremendous efforts with using suitable antibiotics in order to improve from bacterial infection, purulent pericarditis has the ability to complicate with cardiac tamponade leading to death. *Streptococcus pneumoniae* purulent pericarditis in a neonate -although a rare occasion- had been reported from New York which was serotype 7F (19). A 67 year-old woman was also declared as a Danish report indicating that both old and lower ages may be infected via same offending agent (20). This elder had admitted with massive pericardial fluid. The patient was treated successfully with drainage and intravenous penicillin. Early diagnosis, aggressive pericardial drainage and appropriate antibiotic therapy are written to be essential (20). Some case reports point out that effective antibiotherapy will prevent unnecessary pericardial window opening and thoracotomy procedures (21). Rare weak organisms may also cause dramatic pictures as in case of 6-month-old male infant in whom *Lactobacillus iners* had been responsible for pericarditis (22).

Tuberculosis (TB) has a several implications as a cause of pericarditis owing to not only its chronicity but also

its increased deleterious effect in association with HIV. It has been shown that HIV-associated TB pericarditis is a more aggressive disease with a greater degree of myocardial involvement (23). Patients have larger pericardial effusions with more frequent hemodynamic compromise and more significant ST segment changes in the electrocardiogram. This is because HIV alters the natural history and outcomes of TB pericarditis. Again, it has been announced that TB is the cause in greater than 85 % of cases of pericardial effusion in HIV-infected cohorts (23). Co-infection with HIV has resulted in a number of areas of uncertainty. The mechanisms of myocardial dysfunction are unclear, new methods of improving the yield of TB culture and establishing a rapid bacterial diagnosis remain a major challenge, the optimal duration of anti-TB therapy has yet to be established, and the role of corticosteroids has yet to be resolved (23).

Likewise TB infected HIV- positive immunocompromised patients, patients with lymphoma are also susceptible to less frequently seen microorganisms. Infectious pericarditis due to *Bordetella holmesii* in an adult patient with malignant lymphoma is such an example (24). Sarcoidosis is also a chronic disease of unknown origin but well known for its immunodepressant effect. Its association with purulent pericarditis leading to tamponade had been experienced by French authorities (25). *Listeria monocytogenes* is a fearful organism of central nervous system manifestations. It is fairly rare in cardiac occasions-only association with infective endocarditis is commonly written in classic medical books. However, chronic liver failure patient with Child Class B classification had been presented with pericarditis of this origin and successfully treated with ampicillin and pericardiectomy (26), thus again reminds opportunistic rare bacterial involvement of the pericarditis scene.

### Parasites and Pericarditis

Parasites such as leishmaniasis have also been reported to cause panniculitis type of pericarditis after antimony treatment (27). Histopathologic examination revealed was a nodular vasculitis. Culture and PCR of the microorganism do have diagnostic value. Amebiasis is a well known parasite with a characteristic feature of bowel disease presenting with bloody diarrhea in most cases. Amebic pericarditis is rare but this infection is usually a secondary complication due to pathophysiologically, pyogenic liver abscesses with hepato-pericardial fistula, leading

to acute cardiac tamponade (28). However, perforation of liver abscess into pericardial sac is quite rare. There have been only 3 reports (29-31) in the literature pointing out 3 cases of amebic pericarditis infection in the Thai population, of which 1 case was lethal. Another liver abscess history written from Malaysia emphasizes the importance of this possible pericarditis complication especially in case of cardiac arrhythmia association (32). A marked peripheral blood eosinophilia was observed, and the eruption was diagnosed as urticaria in a young woman presenting with pericardial effusion and cholecystitis with a high titer of antibody against *Ascaris lumbricoides* (33). Treatment with albendazole drastically improved all clinical manifestations along eosinophilia.

Manifestations of cardiac hydatid disease which is again very rare, even in endemic regions of the world include chest pain, anaphylactic shock, constrictive pericarditis, congestive heart failure, and arterial embolism. Surgery is announced to be the exclusive therapy, where the cysts are excised during open-heart surgery which should be performed carefully, given the potential complications that surgery may bring. A 32-year-old male patient was admitted with chest pain, weight loss, lethargy, and dizziness and transesophageal echocardiography study revealed a cystic mass adjacent to the left ventricular posterior wall (34). Diagnosis of hydatidosis was confirmed with serologic tests (ELISA and indirect immunofluorescence). Today, several regions of the world for example, the Mediterranean countries, the Middle East, South America, and East Africa are frequently seen areas of the planet. Sometimes it is impossible to effectively complete the surgical procedure without compromising anterosuperiorly displaced left anterior descending artery (LAD) which will need a bypass repair of the injured one (34). Albendazole is the selective medication after the operation.

A French article publishes a young man with an aberrant migration of *Dracunculus medinensis* from an endemic zone of bilharziasis and dracunculosis in Côte d'Ivoire (35). There was a thrombus in the right atrium leading to death owing to refractory cardiac insufficiency. It was also a case of a relapsing pericarditis. Filariasis, a mosquito-borne disease which is wide spread in India. While laboratory diagnosis has been conventionally done by demonstrating microfilaria in peripheral blood smears, occasionally they are reported in various body fluids including pericardial fluid. A 33-year-old man with severe dyspnoea and chest pain,

referred from a private nursing home with a diagnosis of unresolving pericarditis (36). Tropical diseases must always be considered in the etiological diagnosis of pericardial effusion. Chagas' disease, the most important parasitic infection of the heart is currently considered a global parasitic infection due to the growing migration of populations from areas where these infections are highly endemic to settings where they are not endemic. The lack of effective vaccines, optimal chemoprophylaxis, or evidence-based pharmacological therapies to control many of the parasitic diseases of the heart, in particular Chagas' disease, makes this disease one of the most important public health challenges of our time (37). A case of acute pericarditis associated with recurrent *Plasmodium ovale* malaria is a French article published last year (38). It is about a soldier whose mission was in West Africa. A history of travel to endemic countries should remind of this type of infestation. A favorable clinical outcome was achieved using chloroquin (30 mg/kg on 6 days) in association with NSAID followed by salicylates for one month, the authors write. A group of scientist from Washington University School of Medicine investigated the chest computed tomography (CT) findings of North American paragonimiasis and found higher rates of pericarditis in their series (39).

#### **Constrictive infectious pericarditis**

Inflammation in the pericardium may result in calcification in some further deteriorating the myocardial functioning owing to constrictive pericarditis (CP). In case of the compression localized at right cardiac chambers, it may eventually help develop pseudocirrhosis. Idiopathic CP although old TB agent may also be responsible will exhibit a clinical picture of exertional dyspnea, prominent neck veins, ascites, positive hepatjugular reflux, significant hepatomegaly. Chest X-ray, transthoracic echocardiography, CT and magnetic resonance imaging (MRI) may help diagnose the condition. Plain x-ray will reveal a circumferential pericardial calcification. Electrocardiography may show atrial fibrillation or sinus tachycardia with low voltage in all derivations and accompanying diffuse nonspecific T-wave inversions. On occasions where transesophageal echocardiography showing a thickened pericardium is also important since progressive dyspnea on exertion and lower extremity edema which may also be associated with right-sided pleural effusion may cause a misdiagnose of heart failure. Echo will also demonstrate preserved right and left ventricular systolic function in these cases. Constrictive

filling pattern demonstrated with doppler Doppler echocardiography is almost the same pattern with restrictive cardiomyopathy (40).

PVB19 has been report to be the cause of effusive-constrictive pericarditis in human (41). C-reactive protein (CRP) levels are found to be important in the differential diagnosis of both conditions-latter will have lower levels- (42). In case of cirrhosis-like symptoms constrictive pericardities also should be kept in mind. The pathophysiology of transient constrictive pericarditis is not clearly confirmed but may be due to transient thickness and loss of elasticity caused by inflammation, fibrin deposition, and edema (43). The definitive treatment for constrictive pericarditis is pericardi-ectomy (44) but according to Haley et al. (45) transient constrictive pericarditis can be resolved in 3 months by conservative medical treatment, including NSAIDs or steroids. If constrictive pericarditis is indicated in a hemodynamically stable patient, medical treatment should be considered over pericardiectomy in the early phase. A case of acute CP in a healthy subject infected by H1N1 virus had been reported (46). Although there may be an association between fulminant myocarditis and Swine influenza, cardiovascular complications resulting from swine influenza A infection are exceedingly rare. The clinical course and response to medical treatment of acute pericarditis as a complication of H1N1 influenza infection showed no difference from acute pericarditis due to any other cause (46). CP is a relatively rare complication of viral or idiopathic acute pericarditis (<0.5%) but in contrast, is relatively frequent for specific etiologies, especially bacterial (47). From 2000 to 2008, 500 consecutive cases were prospectively studied to evaluate the CP in this study (47). Etiologies found were viral/idiopathic in 83.2%, connective tissue disease/pericardial injury syndromes in 7.2%, neoplastic pericarditis in 5.0%, tuberculosis in 4.0%, and purulent in 0.6%. The incidence rate of CP was 0.76 cases per 1000 person-years for idiopathic/viral pericarditis, 4.40 cases per 1000 person-years for connective tissue disease/pericardial injury syndrome, 6.33 cases per 1000 person-years for neoplastic pericarditis, 31.65 cases for 1000 person-years for tuberculous pericarditis, and 52.74 cases per 1000 person-years for purulent pericarditis.

#### **Myxedema and Infectious pericarditis**

Myxedema which is untreated form of hypothyroidism that may lead to coma is an extensive swelling of the

soft tissue as well as the fluid collection in the inter-space of the serous constructions such as peritoneum, pleura and pericardium. Edema here is not soft and there is no easily godet formation when one checks on the pretibial region with the index finger due to mucinous liquid collection. Although leading cause for cardiac tamponade has been declared as the malignant origin, and TB and metabolic pericarditis (48) such as uremia and myxedema were less offending reasons in a 10 year of follow-up study (49), pericardial tamponade due to synergistic effects of TB and myxedema has been published in recent year (50). However, TB is a leading cause of massive pericardial effusion and tamponade especially in underdeveloped and developing countries are frequently experienced. Hypothyroidism is also associated with pericardial effusion, but with rare progression to tamponade. This co-incidence case has been treated with four-agents antituberculous and thyroxine replacement therapy and tamponade has been attributed to both conditions' synergistic effect. There has been a review series of cardiac tamponade patients from Cincinnati and myxedema leading to pericardial tamponade in another report was written (51).

#### Crystal pericarditis and tuberculosis

Another form of pericarditis is cholesterol crystal pericarditis which is characterized by the presence of cholesterol crystals in pericardial fluid and may be associated with TB although chronic renal failure, rheumatoid arthritis, myxedema or hypercholesterolemia have all been reported (52,53). Factors responsible for increase in pericardial fluid cholesterol may be its liberation from injured pericardial cells and rheumatoid nodules, lysis of red cells, or lymphatic obstruction and impairment of the absorptive capacity of the pericardium (53). In conclusion; pericardial effusions indicating pericarditis may be due to many reasons other than infectious origin as well such as heart failure, chronic renal failure and rheumatic disease. Effective measures and management procedures for pericarditis should be applied on time with special respect to its etiology.

#### REFERENCES

1. Ball JB, Morrison WL. Cardiac tamponade. *Postgrad Med J* 1997;73(857):141-5.
2. Bishop LH, Estes EH, McIntosh HD. The electrocardiogram as a safeguard in pericardiocentesis. *J Am Med Assoc* 1956;22;162(4):264-5.
3. Maggiolini S, Osculati G, Vitale G. Utility and safety of diagnostic pericardiocentesis. *Eur Heart J* 2005;26(10):1046-7.
4. Vayre F, Lardoux H, Pezzano M, Bourdarias JP, Dubourg O. Subxiphoid pericardiocentesis guided by contrast two-dimensional echocardiography in cardiac tamponade: experience of 110 consecutive patients. *Eur J Echocardiogr* 2000;1(1):66-71.
5. Tsang TS, Enriquez-Sarano M, Freeman WK, et al. Consecutive 1127 therapeutic echocardiographically guided pericardiocenteses: clinical profile, practice patterns, and outcomes spanning 21 years. *Mayo Clin Proc* 2002;77(5):429-36.
6. Cikes I. A new millennium without blind pericardiocentesis? *Eur J Echocardiogr* 2000;1(1):5-7.
7. Duvernoy O, Borowiec J, Helmius G, Erikson U. Complications of percutaneous pericardiocentesis under fluoroscopic guidance. *Acta Radiol* 1992;33(4):309-13.
8. Ozer HO, Davutoglu V, Cakici M, et al. Echocardiography-guided pericardiocentesis with the apical approach. *Turk Kardiyol Dern Ars* 2009;37(3):177-81.
9. Matthew P. Fronheiser and Stephen W. Smith M, *IEEE. Analysis of a Vibrating Interventional Device to Improve 3-D Colormark Tracking. IEEE Transactions On Ultrasonics, Ferroelectrics, and Frequency Control* 2007;54(8):1700-7.
10. Armstrong G, Cardon L, Vilkomerson D, et al. Localization of needle tip with color doppler during pericardiocentesis: In vitro validation and initial clinical application. *J Am Soc Echocardiogr* 2001;14(1):29-37.
11. Fronheiser MP, Real-Time 3D Color Flow Doppler for Guidance of Vibrating Interventional Devices. *Ultrasonic imaging* 2004;26:71-84.
12. Klein SM, Fronheiser MP, Reach J, Nielsen KC, Smith SW. Piezoelectric vibrating needle and catheter for enhancing ultrasound-guided peripheral nerve blocks. *Anesth Analg* 2007;105(6):1858-60.
13. Klein SV, Afridi H, Agarwal D, Coughlin BF, Schielke LH. CT directed diagnostic and therapeutic pericardiocentesis: 8-year experience at a single institution. *Emerg Radiol* 2005;11(6):353-63.