



Angiomyofibroblastoma of Vulva

Emel Kurtoglu¹, Rabia Kaya², Nevin Topak³

ABSTRACT

Angiomyofibroblastoma is a rare, benign, well-circumscribed neoplasm predominantly occurring in the pelvipereineal region of middle-aged women. The tumour cells are round-to-spindle shaped concentrated around vessels. They almost have immunoreactivity for desmin and vimentin, consistently positive for estrogen and progesterone receptors, occasionally positive for CD 34. The complete surgical excision of the tumour is necessary. It is important to distinguish this tumour from especially aggressive angiomyxoma to avoid inadequate treatment. Here, we report a case of vulvar angiomyofibroblastoma in a 46-year old postmenopausal woman whose findings were differentiating from others. Histologically, the tumour involved fibroadipose tissue and immunoreactivity for desmin and actin was negative.

Key words: Angiomyofibroblastoma, vulva, postmenopause

Vulvanın Anjiomyofibroblastoması

ÖZET

Anjiyomiyofibroblastom, genellikle orta yaş kadınlarda, pelvipereanal bölgede ender olarak görülen, çok iyi sınırlı selim bir tümördür. Tümör hücreleri damarlar etrafında içi daireler şeklinde yerleşmişlerdir. Hemen her zaman desmin ve vimentin, sürekli olarak östrojen ve progesteron reseptörleri için olmakla birlikte bazen de CD 34 için immünreaktiflerdir. Cerrahi tedavide tam ekzizyon gereklidir. Yetersiz tedaviden kaçınmak için, tümörü agresif anjiyomiksomdan ayırt etmek oldukça önemlidir. Burada, 46 yaşında postmenopozal dönemdeki bir kadın hastada, farklı histopatolojik bulguları olan bir vulvar anjiyomiyofibroblastom olgusu sunulmaktadır. Tümör hücreleri fibrodipoz doku içermekte ve desmin ve aktin için negatif immünreaktivite göstermektedir.

Anahtar kelimeler: Anjiyomiyofibroblastom, vulva, postmenopoz

INTRODUCTION

Angiomyofibroblastoma (AMFB) is a rare, well-circumscribed mesenchymal neoplasm, usually arising in the pelvipereineal region, especially the vulva and apparently composed of stromal cells distinctive to this anatomic region (1). It was first described by Fletcher et al. in 1992 as a new entity (2). This tumour arises predominantly in females, principally in adults between menarche and menopause (2-6). Ten percent (10%) of patients are postmenopausal and rare cases occur in males which are defined as male angiomyofibroblastoma-like tumour (2,6). Most cases present as a slowly enlarging, painless, circumscribed mass and are often misdiagnosed as a Bartholin's gland cyst and hydrocele of the canal of Nuck (7,8). These lesions are well-circumscribed but not encapsulated with a thin-pink cut

surface and soft consistency (1). Histologically, these tumours show varying cellularity with prominent vessels. The vessels are mostly small, thin-walled, ectatic and are set in an abundant loose, oedematous stroma. The tumour cells are round-to-spindle shaped with eosinophilic cytoplasm and typically are concentrated around vessels. Mitosis are rare (1). The majority of cases have immunoreactivity for desmin and vimentin. They are consistently positive for estrogen and progesterone receptors, occasionally positive for CD 34 and negative for S100 protein, keratin and fast myosin (9,10). The recommended treatment is complete surgical excision of the tumour. Although these tumours doesn't tend to recur locally, follow-up examination is necessary (9). Histopathological differential diagnosis include cellular angiomyofibroma, aggressive angiomyxoma, myxoid li-

¹Departments of Obstetrics and Gynecology and ²Pathology, Ereğli, Konya, Turkey ³Department of Pathology, Karaman, Turkey

Received: 01.07.2011, Accepted: 24.08.2011

Correspondence: Dr. Emel Kurtoglu
Ereğli Devlet Hastanesi, Ereğli, Konya

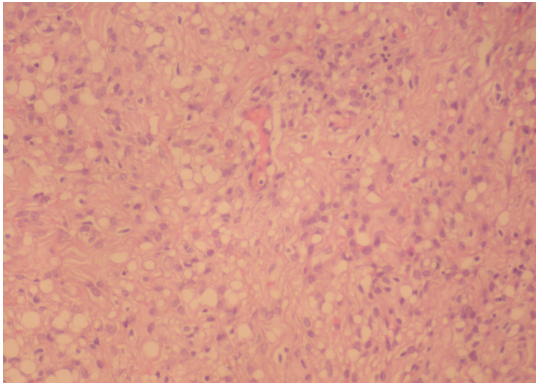


Figure 1. Capillary structure and scattered adipocytes (H/E X40)

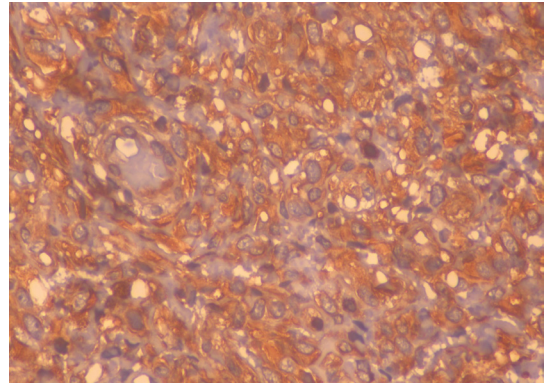


Figure 3. Strong and diffuse vimentin positivity (Vimentin x40)

poma, myxoid liposarcoma and myxoid neural tumours (11-13). Here, a case of angiomyofibroblastoma is presented.

CASE

A 46-year-old postmenopausal woman presented with a painful, slow-growing vulvar mass. The patient gave a history of small nodular mass in her vulvar region starting nine years before, which had grown slowly and became painful during the last two months. On physical examination, a soft, mobile and painful mass, measuring almost 4x3x2 cm, was seen in the left labia majora. The patient had no medical and family history of note except being a hepatitis B carrier. There was no abnormality on vaginal examination, pelvic ultrasonography imaging and laboratory examination. A simple tumour

excision was performed to the patient. Macroscopically, the resected tumour had a brownish soft appearance, measuring 3x4x3 cm. Microscopically, fibroadipose tissue (Figure 1), having hypo- and hypercellular areas with capillary blood vessels and mast cells were seen (Figure 2). There was no atypical mitosis. In immunohistochemistry, tumour cells were strongly positive for vimentin (Figure 3), CD 34 (Figure 4), estrogen and progesterone receptors, focal positive for S-100 protein and negative for desmin, actin and pancytokeratin. The index of Ki 67 in cellular areas was 4%.

DISCUSSION

AMFB is a rare and usually benign mesenchymal tumour that predominantly involves premenopausal women, but we report a 46-year-old postmenopausal patient

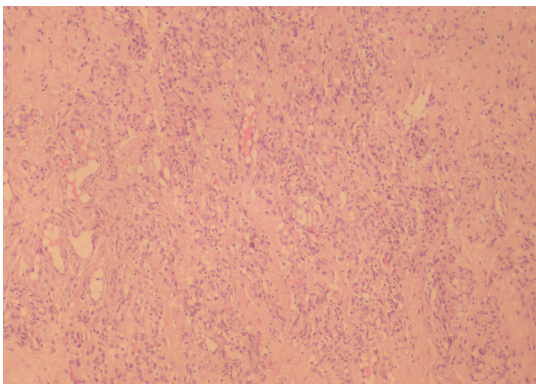


Figure 2. Vascular and capillary-like structure in a loose matrix (H/E X20)

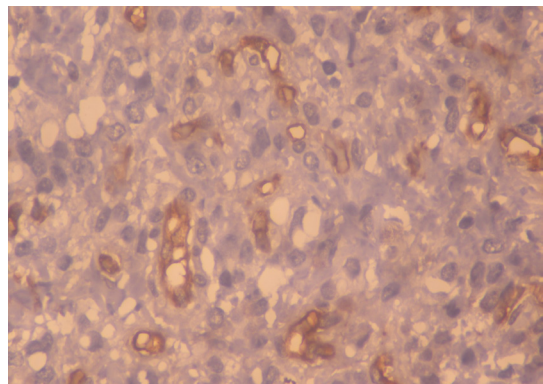


Figure 4. Endothelial cells are positive for CD 34 (CD 34X40)

who presented with a vulvar AMFB. The tumour has a predilection for lower genital tract of women and men, especially for the vulvar region as in the our patient. But unusual regions of female and male can be involved like fallopian tube, perianal region, retroperitoneal and male inguinal region (8,10,12,14). Most cases measure less than 5 cm in maximum diameter, as in the our case, although rare examples measuring up to 10 cm have been recognized (1). Nagai K et al. reported a huge pedunculated AMFB of the vulva at a 48-year-old woman, which was 23 cm in diameter and weighed 4534 g (4). There are only a few case reports of huge AMFB in the literature (9,16). Angiomyofibroblastoma has characteristic histomorphologic features and shows myofibroblastic differentiation. The tumours are generally well demarcated by a thin fibrous pseudocapsule and have alternating hypo- and hypercellular areas with abundant thin-walled blood vessels which were surrounded by stromal cells within an oedematous to collagenous matrix (9). Ten percent (10%) of cases have a variably prominent well differentiated adipocystic component in postmenopausal patients as in our patient (1). Immunoreactivity for desmin and vimentin is detected in the majority of tumour cells, which are consistently positive for estrogen and progesterone receptors (1,9). But in postmenopausal women, desmin staining may be reduced and absent, and also in pregnancy, the tumour cells can be negative for estrogen and progesterone receptors (1,13). In our case, immunoreactivity for desmin was negative, too. As some cases show morphologic overlap with cellular angiofibroma and aggressive angiomyxoma, it is too important to recognize AMFB and distinguish it from other overlapping tumours, especially aggressive angiomyxoma to avoid inadequate treatment. AMFB is entirely benign, does not recur locally, even after marginal local excision although aggressive angiomyxoma has a local recurrence rate of approximately 30% and has a rare metastatic potential (1,16,17). We have had no involvements that might raise the question of bias in the work reported or in the conclusions, implications or opinions stated.

REFERENCES

1. Fletcher CDM, Angiomyofibroblastoma. In Fletcher CDM, Unni KK, Mertens F, eds. *WHO Classification of Tumours. Pathology and Genetics of Tumours of Soft Tissue and Bone. Chapter 2: Fibroblastic/myofibroblastic tumours.* Lyon: IARC Press 2002: 71-2
2. Fletcher CD, Tsang WY, Fisher C, Lee KC, Chan JK. Angiomyofibroblastoma of the vulva. A benign neoplasm distinct from aggressive angiomyxoma. *Am J Surg Pathol* 1992;16:373-82
3. Fukunaga M, Nomura K, Matsumoto K, Doi K, Endo Y, Ushigome S. Vulvar angiomyofibroblastoma. Clinicopathologic analysis of six cases. *Am J Clin Pathol* 1997;107:45-51
4. Laskin WB, Fetsch JF, Tavassoli FA. Angiomyofibroblastoma of the female genital tract: analysis of 17 cases including a lipomatous variant. *Hum Pathol* 1997;28:1046-55
5. Nielsen GP, Rosenberg AE, Young RH, Dickersin GR, Clement PB, Scully RE. Angiomyofibroblastoma of the vulva and vagina. *Mod Pathol* 1996;9:284-91
6. Ockner DM, Sayadi H, Swanson PE, Ritter JH, Wick MR. Genital angiomyofibroblastoma. Comparison with aggressive angiomyxoma and other myxoid neoplasms of skin and soft tissue. *Am J Clin Pathol* 1997;107:36-44
7. Canales BK, Weiland D, Hoffman N, et al. Angiomyofibroblastoma-like tumors (cellular angiofibroma). *Int J Urol* 2006;13:177-9
8. Perko Z, Durdov MG, Druzijanic N, Kraljevic D, Juricic J. Giant perianal angiomyofibroblastoma-a case report. *Coll Antropol* 2006;30:243-6
9. Barat S, Tirgar-Tabari S, Shafae S. Angiomyofibroblastoma of the vulva. *Arch Iran Med*, 2008;11:224-6
10. Quintero C, Saska H, Houck KL, Hernandez E. Angiomyofibroblastoma of the retroperitoneum: a case report. *J Report Med* 2007;52:741-4
11. Micheletti AM, Silva AC, Nascimento AG, Da Silva CS, Murta EF, Adad SJ. Cellular angiofibroma of the vulva: case report with clinicopathological and immunohistochemistry study. *Sao Paulo Med J* 2005;123:250-2
12. Ito M, Yamaoka H, Sano K, Hotchi M. Angiomyofibroblastoma of the male inguinal region. *Arch Pathol Lab Med* 2000;124:1679-81
13. Cetinkaya K, Al RA, Gursan N. Angiomyofibroblastoma of the vulva during pregnancy. *J Obstet Gynecol Res* 2011;37: 1162-5
14. Kobayashi T, Suzuki K, Arai T, Sugimura H. Angiomyofibroblastoma arising from the fallopian tube. *Obstet Gynecol* 1999;94:833-4
15. Nagai K, Aadachi K, Saito H. Huge pedunculated angiomyofibroblastoma of the vulva. *Int J Clin Oncol* 2010;15:201-5
16. Fetsch JF, Laskin WB, Lefkowitz M, Kindblom LG, Meis-Kindblom JM. Aggressive angiomyxoma: a clinicopathologic study of 29 female patients. *Cancer* 1996;78:79-90
17. Granter SR, Nucci MR, Fletcher CD. Aggressive angiomyxoma: reappraisal of its relationship to angiomyofibroblastoma in a series of 16 cases. *Histopathology* 1997;30:3-10.