

Stauffer Syndrome-Dependent a Giant Renal Tumor

Ahmet Çamtosun¹, Erkan Olcücüoğlu¹, Metin Yigman¹, Gulden Aydog², Sait Bicer¹, Oner Odabas¹

ABSTRACT

Renal cell carcinoma is associated with a wide spectrum of para-neoplastic syndromes, which may be precursors of primary or recurrent disease. Non-metastatic hepatic dysfunction in patients suffering from renal cell carcinoma is known as Stauffer's syndrome. It is associated with the production of cytokines by the tumour, and several biochemical abnormalities, including elevated serum alkaline phosphatase and γ -glutamyltransferase.

Key words: Satauffer's syndrome, renal cancer, interleukin, cytokine,

Büyük Böbrek Tümörüne Bağlı Stauffer Sendromu

ÖZET

Renal hücreli karsinomlar da primer ve sekonder olarak tümöre bağlı gelişen pek çok paraneoplastik sendrom vardır. Renal hücreli karsinomu olan hastalarda karaciğer metastazı olmadan karaciğer fonksiyon bozukluğu stauffer sendromu olarak bilinir. Bu sendrom tümör tarafından üretilen stokinlerle ilişkili olarak serum alkalin fosfataz ve gama glutamil transferaz enzimlerinde yükselme olmak üzere ciddi biyokimyasal anormallikleri içerir.

Anahtar kelimeler: Satauffer's sendromu, renal kanser, interlökin, sitokin

INTRODUCTION

Renal cell carcinoma (RCC) is related with about 20% prevalence of para-neoplastic syndromes. Some patients may be the first sign of the disease paraneoplastic syndromes and facilitate its recognition in the early diagnosis of RCC (1-3). Stauffer in 1961; RCC patients suffering with abnormal liver function tests and histological changes consistent with non-specific hepatitis, hepatosplenomegaly and established links with the improvement of these abnormalities after nephrectomy (4). Impairment of liver function tests; In the absence of liver metastasis made by tumor including interleukin-6, depending on many cytokines patients suffering from RCC with approximately 10 - 15% is seen in (5,6). It is associated with fever, weight loss and poor prognosis (7). We report a case of a old woman presenting with non-specific constitutional symptoms and a notable isolated elevation of cholestatic liver enzymes.

CASE

A 74-year-old housewife who lived in a small town, was

admitted to the hospital because of a 6-month history of anorexia, 10-kg body weight loss, fatigue and malaise. There was no family history of autoimmune disease and cancer. She had not smoked, and did not consume alcohol or use illegal drugs. She had not travelled abroad recently. On physical examination, the patient appeared chronically ill, weighed 40 kg, was 160 cm tall, with a body mass index of 15.6. Her temperature was 37.8°C, blood pressure 100/60 mmHg, and heart rate 90 bpm. The thyroid gland was not palpable and was non-tender. The abdominal examination was palpable right kidney. The most prominent laboratory abnormality was elevated serum liver enzymes, consistent with cholestasis, including alkaline phosphatase (ALP) at 461 U/L (normal < 105 U/L) and γ -glutamyltransferase (GGT) at 153 U/L (normal < 36 U/L), aspartate aminotransferase (AST) at 59 U/L (normal < 32), alanine aminotransferase (ALT) at 50 U/L (normal < 33). Serum bilirubin was normal. Hemoglobin was 10.3 g/dl (12-15.5), white cell 5,590/mm³ (3900-11700), with a normal differential count, platelets 220,000/mm³ (150000-440000), mean corpuscular volume 73 fL (78.5-96.4) MPV: 9.4fL (6.3-9.1), RDW: 17.1 % (11.3 - 14.7), total serum protein

Türkiye Yüksek İhtisas Hastanesi, Department of Urology¹, Department of Pathology² Ankara, Turkey

Received: 15.01.2014, Accepted: 12.09.2014

Correspondence: Ahmet Camtosun
Türkiye Yüksek İhtisas Hastanesi, Department of Urology Sıhhiye, Ankara, Turkey
E-mail: drcamtosun@yahoo.com
Tel: + 90 312 306 18 29

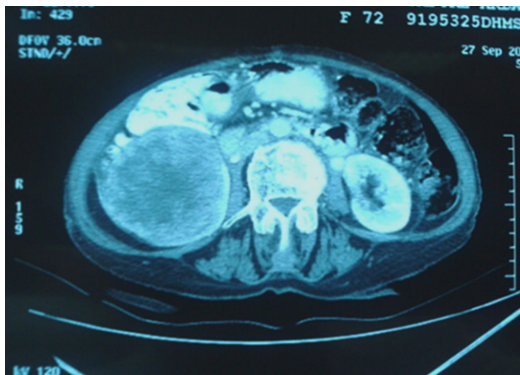


Figure 1. Obtained after oral and intravenous administration of contrast material, revealing a highly heterogenous renal mass, which contained multiple necrotic areas and zones of solid enhancement

5.78 g/dl(6.6-8.7), and albumin 2,27 g/dl(3.5-5.2). The urinalysis showed hematuria, blood and urine cultures were sterile. On ultrasound of the abdomen a 10-cm in diameter solid mass was present in the mid-lover portion of the right kidney and minimal abdominal fluid was found. No other organ abnormality was observed. An abdominal computed tomography (CT) scan (Figure 1), obtained after oral and intravenous administration of contrast material, confirmed the results of ultrasonography, revealing a highly heterogenous renal mass, which contained multiple necrotic areas and zones of solid enhancement. The right renal vein and contralateral kidney were normal. There was no abdominal lymphadenopathy or liver metastasis. Distant metastases were absent on chest CT scans. After the right kidney was surgically excised, a 9× 8 × 7.5 cm tumour was found within the central parenchyma, which, on gross examination, dislodged but did not invade the renal pelvis and calyces. A Fuhrman nuclear grade 4 (Figure-2),

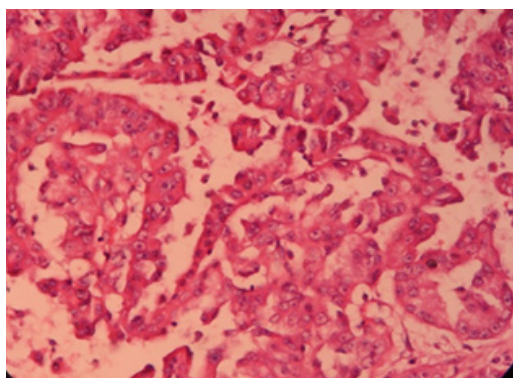


Figure 3. Papillary cell (CD10 positive)

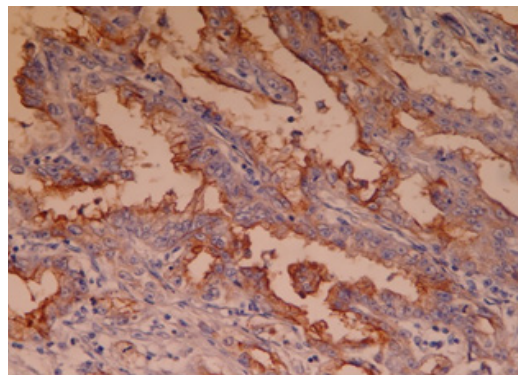


Figure 2. Fuhrman nuclear grade 4

papillarycell (Figure-3), clear-cell (Figure-4) and sarcomatoid differenciacion renal-cell carcinoma (Figure-5) was present on histological examination, but not invade the renal capsule and the perirenal fat. The surgical margins were free of tumour. Cytological examination of the abdominal fluid showed no malignant cells. The patient made an uneventful postoperative recovery. At 12 month of follow-up, the patient is afebrile and has regained weight. Her appetite has returned and she feels well. The serum concentrations of cholestatic liver enzymes have returned to normal.

DISCUSSION

In patients with diabetes mellitus, hyperthyroidism, psychiatric disorders, infections, drug use, drug use, malabsorption syndromes can increase the deterioration in liver function enzymes and cholestasis (8). Our patient fatigue, weight loss, low-grade fever and lack of inflammatory and neoplastic diseases had led. The patient in absence of hypertransaminasemia and that were the main laboratory findings of elevated alkaline phosphatase and GGT. Intrahepatic and extrahepatic cholestasis in this case was consistent with normal serum bilirubin concentration though. Our patient did not use the drug and were excluded drugs may cause liver damage. Elevations in liver enzymes capable of thyrotoxicosis are other causes have been without the normal hormonal measurements. Finally, primary sclerosing cholangitis and primary biliary cirrhosis diagnosis was ruled out with negative immunologic research.

Kidney tumors, which are characterized by various and ambiguous attitude, and therefore constitutes the paradigm of a hidden disease (9). Because renal cell carci-

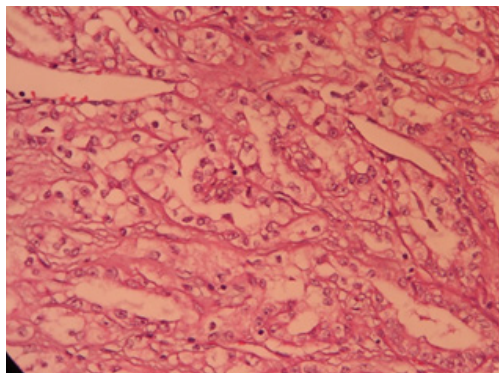


Figure 4. Clear cell component

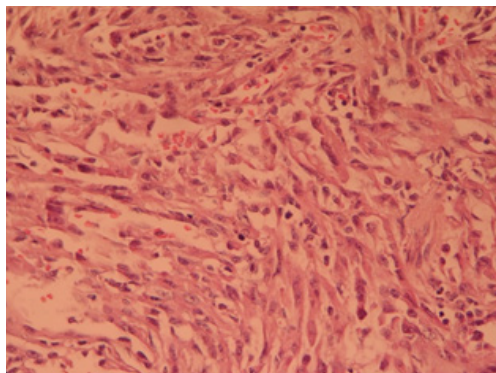


Figure 5. Tumor components with sarcomatoid morphology

noma multiple initial signs and symptoms, often due to systemic and non-specific, "internist tumor" to be known as. Hematuria, abdominal pain and abdominal masses to be seen together; Approximately 10% of patients with classic triology from less visible (10). Stauffer syndrome; kidney tumors in the liver in the upper abdomen ultrasonography performed in the presence of a surprising way, intrahepatic or extrahepatic bile duct is not detected any abnormality associated with the expansion and bile ducts and jaundice is very rare (11). While our patient had microscopic hematuria, abdominal mass and did not abdominal pain. Abdominal mass and hematuria led us to be made in the kidney tumor and upper abdominal ultrasonography performed with the presence of a kidney tumor liver and intrahepatic or extrahepatic bile duct with bile as demonstrated no abnormalities related expansion. There was no abdominal lymphadenopathy or liver metastasis. Distant metastases were absent on chest CT scans.

Stauffer syndrome after nephrectomy in liver enzymes and decreased to normal levels postoperative follow-up of liver enzymes rise again if this is a sign of local recurrence or metastatic disease (12). Our patient liver enzymes returned to normal 2 weeks after the surgery and Who was monitored postoperative smoothly 12 months.

Stauffer syndrome may precede other manifestations of renal cell carcinoma. In case of unexplained abnormal liver function, particularly in presence of systemic symptoms, underlying renal cell carcinoma should be excluded by focused investigations.

REFERENCES

1. Laski ME, Vugrin D: Paraneoplastic syndromes in hypernephroma. *Semin Nephrol* 1987;7:123-30.
2. Gold PJ, Fefer A, Thompson JA: Paraneoplastic manifestations of renal cell carcinoma. *Semin Urol Oncol* 1996;14:216-2.
3. Bedke J, Buse S, Kurosch M, Haferkamp A, Jäger D, Hohenfellner M. Paraneoplastic syndrome in renal cell carcinoma. *Urologe A* 2007, 46:45-8.
4. Stauffer MH: Nephrogenic hepatosplenomegaly. *Gastroenterology* 1961;40:694.
5. Boxer RJ, Waisman J, Lieber MM, Mampaso FM, Skinner DG: Nonmetastatic hepatic dysfunction associated with renal carcinoma. *J Urol* 1978;119:468-71.
6. Blay JY, Rossi JF, Wijdenes J, et al. Role of interleukin-6 in the paraneoplastic inflammatory syndrome associated with renal-cell carcinoma. *Int J Cancer* 1997;72:424-30.
7. Malnick S, Melzer E, Sokolowski N, Basevitz A. The involvement of the liver in systemic diseases. *J Clin Gastroenterol* 2008;42:69-80.
8. Kranidiotis GP, Voidonikola PT, Dimopoulos MK, Anastasiou-Nana MI. Stauffer's syndrome as a prominent manifestation of renal cancer: a case report. *Cases J* 2009;13;2(1):49.
9. Papac RJ, Poo-Hwu WJ. Renal cell carcinoma: a paradigm of lanthanid disease. *Am J Clin Oncol* 1999;22:223-31.
10. Motzer RJ, Bander NH, Nanus DM. Renal-cell carcinoma. *N Engl J Med* 1996;335:865-75.
11. Giannakos G, Papanicolaou X, Trafalis D, Michaelidis I, Margaritis G, Christofilakis C. Stauffer's syndrome variant associated with renal cell carcinoma. *Int J Urol* 2005;12:757-9
12. Chuang YC, Lin AT, Chen KK, Chang YH, Chen MT, Chang LS. Paraneoplastic elevation of serum alkaline phosphatase in renal cell carcinoma: incidence and implication on prognosis. *J Urol* 1997;158:1684-7.