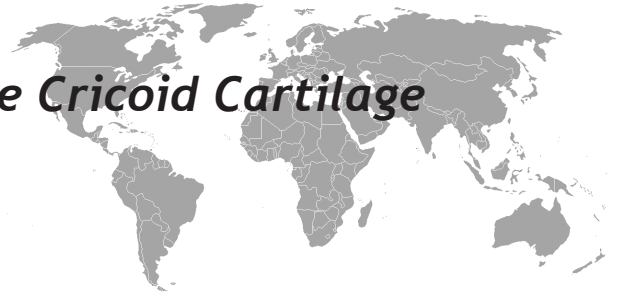


Osteophyte Arising From The Cricoid Cartilage Causing Dysphagia



Abdussamet Batur, Mehmet Emin Sakarya, Abdulaziz Uslu

ABSTRACT

Although cervical degenerative changes is a common disorder, dysphagia induced by osteophyte formation is uncommon. We present a case of 54-year-old patient suffering dysphagia secondary to cricoidal osteophyte. Physical examination showed no abnormality. A barium esophagography revealed anterior compression of the esophagus at the level of cricoid cartilage. A computed tomography (CT) showed a small spur originating from the cricoid. Magnetic resonance imaging (MRI) demonstrated the osteophyte-induced edema and allowed the differential diagnosis with the other causes of dysphagia. In this report, radiological features of cricoidal osteophyte is presented.

Key words: Dysphagia, cricoid cartilage, osteophyte, paraesophageal edema

Disfajiye Neden Olan Krikoid Kıkırdaktan Kaynaklanan Osteofit

ÖZET

Servikal kemik yapılarında dejeneratif değişiklikler sık görülmekle beraber, osteofitik oluşuma bağlı yutma güçlüğü oldukça nadir görülür. Krikoidten köken alan osteofit basısı nedeniyle yutma güçlüğü çeken 54 yaşındaki erkek hasta merkezimize başvurdu. Fizik muayenede anormallik saptanmadı. Baryumlu özofagus grafisinde, krikoid kıkırdak seviyesinde özofagusu anteriorundan bası bulgusu izlendi. Etiyolojiye yönelik çekilen bilgisayarlı tomografide, krikoidten köken alan spur saptandı. Yumuşak dokunun değerlendirilmesine yönelik elde edilen manyetik rezonans görüntülemeye, osteofit etrafında ödem izlendi ve olası diğer yumuşak doku patolojileri ekarte edildi. Bu olguda, krikoid osteofitin radyolojik bulgularını sunmayı amaçladık.

Anahtar kelimeler: Disfaji, krikoid kıkırdak, osteofit, paraözefagil ödem

INTRODUCTION

There are numerous pathologies causing dysphagia seen in various speciality departments. Some of these lesions are; esophageal inflamatur diseases, motility disfunctions, diverticulum, benign and malignant lesions of the mediastinum, cervical spinal diseases and degenerative diseases of the vertebrae (1,2). Although hypertrophic changes of the cervical spine occur frequently after 5. decades, dysphagia due to the osteophyte compression is very rare (3-7). In this report, a very rarely seen lesion, which we could find no mention in the literature demonstrating osteophyte arising from the cricoid, as a cause of dysphagia has been described radiologically.

Necmettin Erbakan University Meram Faculty of Medicine, Department of Radiology, Konya, Turkey.

Received: 06.06.2012, Accepted: 19.10.2012

CASE

A 54-year-old male was admitted to our center with a three month history of difficulty in swallowing solid foods. Physical examination and laboratory findings were normal. His medical history was unremarkable. A barium esophagography showed anterior compression of the esophagus at the level of cricoid cartilage (Figure 1). Axial computed tomographic (CT) scan gave vent to spur formation, three mm in diameter, extending from the cricoid cartilage to the posterior (Figure 2). The sagittal reconstruction sections revealed osteophyte extending 13 mm caudally (Figure 3). A magnetic resonance imaging (MRI) was performed to rule out soft tissue

Correspondence: Abdussamet Batur, Department of Radiology, Necmettin Erbakan University Meram Faculty of Medicine, Konya, Turkey.
Tel.: +90 332 2236337 Fax: +90 332 2236181
E-mail: drsamet56@yahoo.com

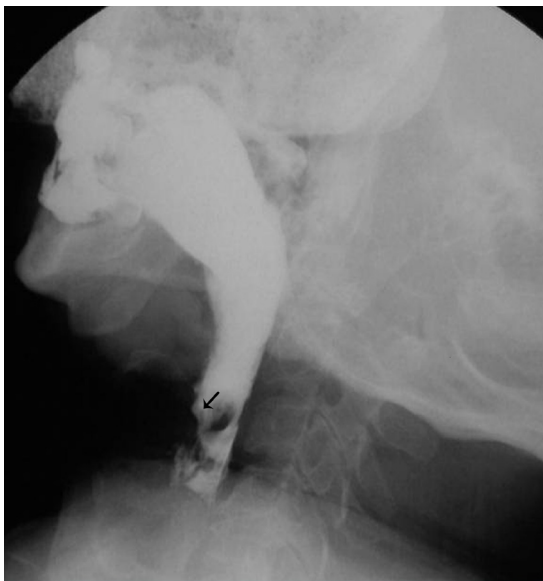

Figure 1. Barium swallow radiograph showing the compression on the anterior side of esophagus (black arrow).

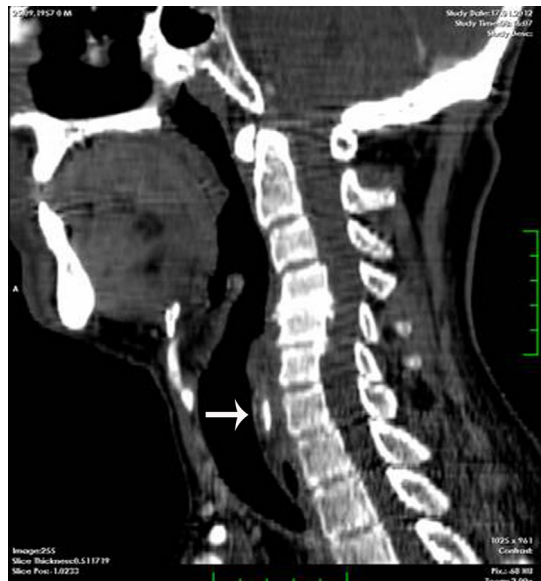

Figure 3. Sagittal reconstructed CT scan showing the elongation of cricoid osteophyte caudally (white arrow).

pathology associated with dysphagia. Paraesophageal inflammatory change adjacent to the osteophyte was observed on MRI (Figure 4).

The patient's difficulty in swallowing was thought to be secondary to the compression of cricoid osteophyte and osteophyte-induced soft tissue edema.

DISCUSSION

Although cervical osteophytes are common in the aging population, dysphagia is rare (4). 3000 cervical spines with degenerative changes were examined and only six of them caused dysphagia (7). Postulated explanations of dysphagia caused by osteophytes include; mechanical

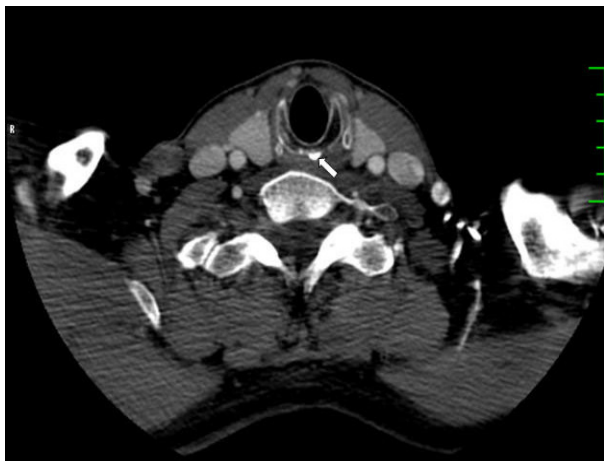

Figure 2. Axial CT scan showing osteophyte arising from the cricoid cartilage (white arrow).

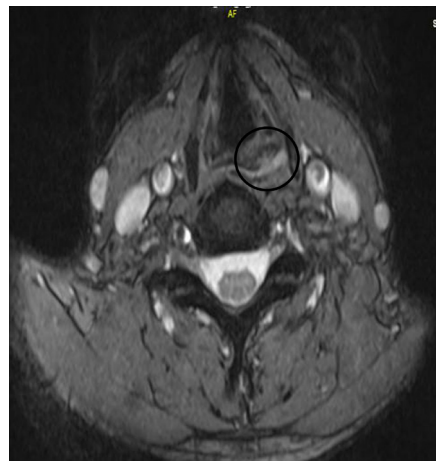

Figure 4. Axial T2-weighted MRI image showing paraesophageal edema (in circle).

blockage of large osteophytes, compression of small osteophytes to the part of esophagus fixed, or osteophyte-induced paraesophageal inflammatory reaction (1). The esophagus is fixed at two points, at the cricoid cartilage and at the diaphragm and the remainder of the esophagus is fairly mobile from the neck to the abdomen (8-10). Thus, at the cricoid cartilage, a small osteophyte can cause dysphagia (9,10).

Some investigators believe that purely mechanical factors cause dysphagia. Other suggest that dysphagia is also caused by parapharyngitis or paraesophagitis in relation to the protrusion inducing fibrosis and adhesions (7,10). In our situation a small osteophyte arising from the cricoidal cartilage caused dysphagia because of its location and the presence of accompanying edema. Radiological diagnostic approach should include lateral x-ray films, barium esophagography, CT and MRI. The inhesion of osteophyte, its compression on esophagus, the craniocaudal and anteroposterior extension of it, and the adjacent inflammatory changes can be demonstrated by lateral plain radiograph, barium esophagography, CT and MRI, respectively (5). To reveal the cause of our patient's dysphagia, we used techniques above mentioned and were able to find out the findings of compression due to cricoid spur, accompanied by edema. For the treatment, conservative approach should be applied primarily. Surgery can be performed in the event of progression or to the distinct symptomatic cases (2,8).

As a result, a small osteophyte arising from cricoid cartilage can cause dysphagia by compressing, because esophagus is fixed at this location. The first method to be used in diagnosis should be lateral cervical radiography and barium esophagography. To show areas of osteophytic elongation or to detect of secondary changes to the degeneration CT or MRI can be used, respectively.

Acknowledgments: Material from this report has not been presented anywhere.

Conflict of interest: The authors declare that they have no conflict of interest.

REFERENCES

1. Zırh TA, Öktenoğlu T, Pamir N, Özer AF, Erzen C. Diffuse idiopathic hypertrophic sclerosis causing dysphagia: a case report. *Turk Norosurgery* 1994;4: 89-93.
2. Pangal S, George J. Cervical Osteoarthropathy: an unusual cause of dysphagia. *Age Ageing* (1999) 28 (3): 321-2.
3. Nakase H, Shin Y, Park Y, Sakaki T. Dysphagia caused by anterior cervical osteophytes. *J Nara Med Assoc* 2005;56:43-8
4. Behrs OH, Schmidt HW. Dysphagia caused by hypertrophic changes in the cervical spine: report of two cases. *Annals of Surgery* 1959; 149; 297-9
5. Giger R, Dulguerov P, Payer M. Anterior cervical osteophytes causing dysphagia and dyspnea: an uncommon entity revisited. *Dysphagia* 2006;21:259-63
6. McCafferty RR, Harrison MJ, Tamas LB, Larkin MV. Ossification of the longitudinal ligament and Forestier's disease: an analysis of seven cases. *J Neurosurg* 1995;83:13-17
7. Bulos S. Dysphagia caused by cervical osteophyte: report of a case. *J Bone Joint Surg Br* 1974;56:148-52
8. Çağavi F, Kalaycı M, Uğur MB, Uzun L, Asil K, Açıkgöz B. Dysphagia and diffuse idiopathic skeletal hyperostosis: case report. *Turk Norosurgery Cilt: 14, Sayı: 2, 146-50, 2004.*
9. Ido K, Hashinati M, Sakamoto A, Urushidani H. Surgical treatment for dysphagia caused by cervical hyperostosis: a report of three cases. *J Orthopaed Traumatol* (2002); 3:55-8
10. Oga M, Mashima T, Iwakuma T, et al. Dysphagia complications in ankylosing spinal hyperostosis and ossification of the posterior longitudinal ligament. Roentgenographic findings of the developmental process of cervical osteophytes causing dysphagia. *Spine* 1993;18: 391-4