

# Giant Cell Tumor of Distal Radius Treated by En-Bloc Resection and Reconstruction by Non Vascularized Fibular Graft

Rajendra G. Malu, Chetan R. Jaju, Vishav Goyal, Santosh Mali, Basavraj Nagoba

## ABSTRACT

Giant cell tumor (GCT) of bone is a benign but locally aggressive tumor with tendency for local recurrence. Here we report a case of giant cell tumor of the right sided distal radius treated by en-bloc resection and reconstruction arthroplasty using autogenous non-vascularized ipsilateral proximal fibular graft. Early radiological union at host-graft junction was achieved at 12 weeks and solid incorporation with callus formation was observed at 20 weeks. Functional range of motion of the wrist was 20 degrees dorsiflexion and 20 degrees palmerflexion. Grip strength was moderate. Soft tissue recurrence and fibulo-carpal subluxation was not observed. Reconstruction arthroplasty of wrist following en-bloc resection of GCT of the distal radius with non-vascularized proximal fibular graft was found useful in preserving the movements and functions as well as stability of the wrist.

**Key words:** Giant cell tumor, distal radius, en-bloc resection, reconstruction arthroplasty, proximal, fibular graft

## Non-Vaskularize Fibula Graft ile En-Blok Rezeksiyon ve Rekonstriksiyon Uygulanan Distal Radius Dev Hücreli Tümörü

### ÖZET

Kemiğin dev hücreli tümörü (GCT) lokal nüks eğilimi olmakla beraber iyi huylu, ancak lokal nüksler ile seyr eden bir tümördür. Bu olgu sunumunda otojen non-vaskularize ipsilateral proksimal fibula grefti kullanılarak en-blok rezeksiyon ve rekonstrüksiyon artroplastisi ile tedavi edilen sağ taraflı distal radius dev hücreli tümörünü sunuyoruz. Konakçı-greft kavşağındaki erken radyolojik kaynama 12 haftada sağlandı ve kallus oluşumu ile solid eklenmesi 20 haftada gözlemlendi. Bileğin hareket fonksiyonel aralığı 20 derece dorsifleksiyon ve 20 derece palmerflexiondu. Kavrama gücü orta idi. Yumuşak doku nüksü ve fibulo-karpal subluksasyon gözlemlenmedi. Non-vaskularize fibula proksimal greft ile distal radius GCT'nin en-blok rezeksiyonu sonrası bileğin rekonstriksiyon artroplastisi bileğin hareketlerini, işlevlerini ve bilek istikrarının korunmasında yararlı bulunmuştur.

**Anahtar kelimeler:** Dev hücreli tümör, distal radius, en-blok rezeksiyon, rekonstriksiyon artroplastisi, proksimal, fibula greft

## INTRODUCTION

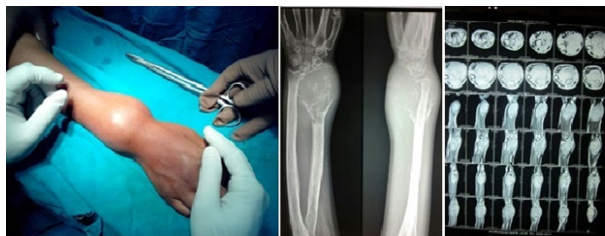Giant cell tumour of bone is a benign but locally aggressive tumor with tendency for local recurrence (1). The distal end of the radius is one of the most commonly involved site of skeletal GCT (10% cases) next to distal femur and proximal tibia (2). Many methods have been advocated for the management of distal radial GCT. Aim of treatment is complete resection of the tumor to de-

crease the chance of any recurrence and to preserve as much wrist function as possible. The treatment consists of either amputation, ulnar translocation with wrist arthrodesis, curettage and bone grafting, curettage with bone cement filling, en-bloc resection of the lesion with subsequent reconstructions (3-5). Although curettage and bone grafting can preserve joint functions, it has been observed that it is associated with high local recurrence rate of 27% to 54% (6-8). Walthar (1911) was the

MIMSR Medical College & Yashwantrao Chavan Rural Hospital, Latur

Received: 25.07.2014, Accepted: 10.11.2014

Correspondence: Dr. B. S. Nagoba  
Assistant Dean (Research & Development), Maharashtra Institute of Medical Sciences & Research, Latur-413 531, M.S., INDIA  
Tel: +912382227587 Mobile: +919423075786/ +917588237531  
E-mail: dr\_bsnagoba@yahoo.com, bsnagoba@gmail.com



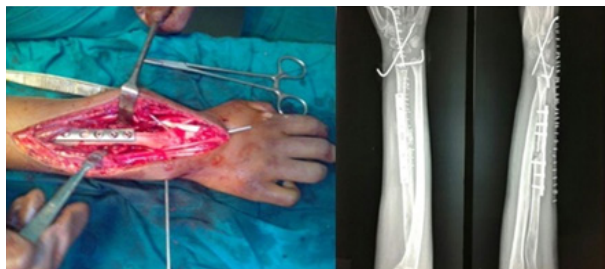**Figure 1.** Pre-operative clinical photograph, radiograph and MRI coronal and sagittal section

first to describe the use of a free non vascular proximal fibular graft to replace the resected distal radius (9). Different success rates have been reported by different workers by using different approaches (10-15).

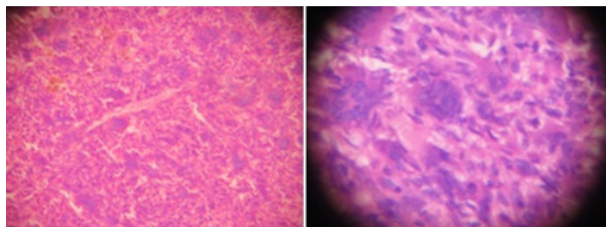
Here, we report a case of giant cell tumor of the right sided distal radius treated by en-bloc resection and reconstruction arthroplasty using autogenous non-vascularized ipsilateral proximal fibular graft.

**CASE**

A 23- year old female presented with swelling and pain in Rt. wrist for the last one and half year. The sudden aggressive increase in swelling and pain was observed since four months. On examination, swelling over the dorsal aspect of distal end of radius around 5 by 10 cm in size was observed. The skin over the swelling was found to be shiny, tense, with raised local temperature and tenderness of grade III with ill-defined margins. The range of movements of wrist joint and hand were grossly restricted with intact neurovascular status. Anteroposterior and lateral radiograph of the Rt. wrist showed an expansile lytic lesion in the subarticular position of the distal radius with break in cortex but

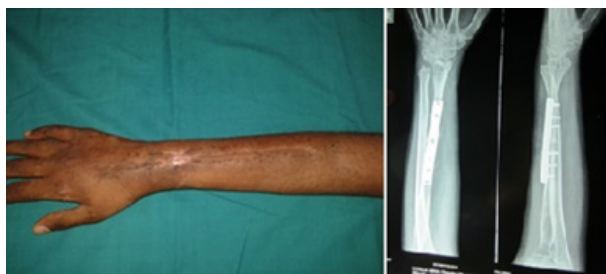

**Figure 2.** Intra-operative photograph showing autogenous fibular graft fixed with K-wires, DCP with bone graft and immediate post-operative radiograph



**Figure 3.** Histopathologic report suggestive of multinucleated tumor giant cells with characteristic stromal cell and inter-cellular collagen.

articular congruity is maintained. Fine needle aspiration cytology (FNAC) report was suggestive of giant cell tumor and as per Enneking classification and staging it was confirmed as aggressive benign tumor stage III (16). MRI was suggestive of lytic expansile destructive bony lesion involving distal end of radius with break in cortex with enhancing large soft tissue mass around 7.7×5.3 cm (Fig. 1). Considering the nature of growth and dominant hand, the case was treated by en-bloc resection and reconstruction arthroplasty using autogenous non-vascularized proximal fibular graft. In this procedure through dorsal approach around 18 cm “S” shaped incision starting from 3 cm distal to the wrist joint and 15 cm extending proximal to wrist was taken and radical en-bloc resection of tumor along with normal 4 cm of distal radius was excised along with the tumor as safe margin. The bone defect after excision of the tumor was 14 cm. Care was taken to preserve the neurovascular bundle while resecting the tumor mass from the surrounding soft tissue. Reconstruction of the bony defect was done using ipsilateral proximal fibular non-vascularised graft of 8 mm more length than actual required was taken to prevent carpo-fibular subluxation. The articular surface of the head of the fibula was placed over the scapho-lu-



**Figure 4.** Follow-up clinical photograph and radiograph after four months

nate articular surface and fixed to the carpals with two 1.5 mm K-wires inserted obliquely. The fibular graft and radius fixed with a 3.5 mm, 8 hole dynamic compression plate (DCP) with 3 screws each in proximal and distal fragments. Another K-wire was inserted transversely to stabilize the newly created fibulo-ulnar joint. Iliac crest cancellous bone grafting was done at the host-graft junction (Fig.2). Histopathologic examination of en-bloc resected part of radius was suggestive of multinucleated tumor giant cells with characteristic stromal cell and intercellular collagen, suggestive of low grade tumor which confirmed the diagnosis of GCT (Fig.3).

The limb was immobilized in a long arm cast for 10 weeks and followed by forearm brace after removing the K-wires for mobilization. Protected brace was continued for another 6 weeks until solid union was achieved radiologically. Routine radiographs were taken at monthly interval to look for signs of union and to exclude local recurrence. Complete union was seen in final radiograph taken at the end of 6 months (Fig.4).

## DISCUSSION

GCT poses a challenge for Orthopaedicians for cure as well as rehabilitation. The goals of treatment are to remove the tumor, reduce the chances of recurrence and preserve the joint functions as much as possible. The defect created by the resection of the distal radius can be filled by non-vascularized autologous proximal fibular graft (10-15). Local recurrence and loss of joint function are still major problems following surgery. Bone grafting or bone cementing after intra-lesional curettage of the tumor has high local recurrence rate. GCT of distal radius is particularly aggressive and has a high rate of local recurrence (7,8). A wide resection of the distal radius GCT when the tumor breaks through the cortex on dorsal and volar sides has been recommended by earlier workers (19, 20). Resection of distal radius and reconstruction with autologous non-vascularized fibula offers several advantages like more congruency of carpal joint, rapid incorporation as autograft and easy accessibility without significant donor site morbidity. Structural change is also minimal. Moreover, immunogenic reactions are absent and bone banking facilities or graft matching procedures are not required. Using vascularized fibular graft to speed up the healing at host-graft junction and reducing the period of immobilization are reported to be inconclusive (18). The oper-

ating time for vascularized fibular graft often reaches 12-14 hours and requires sacrifice of two major vessels. Dissection to obtain the fibula and its vascular pedicle and the isolation of its recipient vessels requires meticulous attention, sophisticated infrastructure, skill and prolonged operating time have made its use limited (17). Hence, considering all factors, the treatment of distal radius GCT with non-vascularised fibular graft is reliable practical technique, which gives optimal result, and is useful in preserving the movements and functions as well as stability of the wrist.

*Conflict of Interest: None to declare*

## REFERENCES

1. Dahlin DC, Cupps RE, Johnson EW. J Giant Cell Tumour: A study of 195 cases. *Cancer* 1970;25:1061-70.
2. Eckardt JJ, Grogan TJ. Giant cell tumour of bone. *Clin Orthop* 1986;204:45-58.
3. Khalil el SA, Younis A, Aziz SA, Shahawy M. Surgical management for Giant cell tumor of bones. *J Egypt Natl Canc Inst* 2004;16:145-52.
4. Chalidis BE, Dimitriou CG. Modified ulnar translocation technique for the reconstruction of giant cell tumor of the distal radius. *Orthopedics* 2008;31:608.
5. Rastogi S, Prasanth I, Khan SA, Trikha V, Mittal R. Giant cell tumour of bone: Is curettage the answer? *Ind J Orthop* 2007;41:109-14.
6. Campanacci M, Baldini N, Boriani S, Sudanese A. Giant cell tumour of bone. *J Bone Joint Surg Am* 1987;69:106-14.
7. Getilis S, Mallin BA, Piasecki P, Turner F. Intralesional excision compared with en bloc resection for giant cell tumour of bone. *J Bone Joint Surg Am* 1993;75:1648-55.
8. Vander Griend RA, Funderburk CH. The treatment of giant cell tumour of distal part of the radius. *J Bone Joint Surg Am* 1993;75:899-908.
9. Walther M. Resection de extremiteinferieure du radius pour osteosarcoma geffe de l extremitessuperiue de perone. *Sac Chir Par Bull Mem* 1911;37:739-47.
10. Murray JA, Schlafly B. Giant cell tumours in the distal end of the radius. Treatment by resection and autograft interpositional arthrodesis. *J Bone Joint Surg Am* 1986;68:687-94.
11. Goni V, Gill SS, Dhillon MS, Nagi ON. Reconstruction of massive skeletal defects after tumour resection. *Ind J Orthop* 1992;26:13-6.
12. Aithal VK, Bhaskaranand K. Reconstruction of distal radius following excision of giant cell tumour. *Int Orthop* 2003;27:110-3.
13. Harris WR, Lehmann EC. Recurrent giant cell tumour after en bloc excision of distal radius and fibular autograft replacement. *J Bone Joint Surg Br* 1983;65:618-20.

14. Deb HK, Das NK. Resection and reconstructive surgery in giant cell tumour of bone. *Ind J Orthop* 1992;26:13-6.
15. Van Demark RE, Jr, Van Demark RE., Sr Non-vascularized fibular autograft to treat recurrent giant cell tumour of the distal radius. *J Hand Surg Am* 1988;13:671-5.
16. Harness NG, Mankin HJ. Giant cell tumour of the distal forearm. *J Hand Surg Am* 2004;29:188-93.
17. Pho RW. Malignant giant cell tumour of distal end of the radius treated by a free vascularized fibular transplant. *J Bone Joint Surg Am* 1981;63:877-84.
18. Intuwongse CS. Reconstruction following resection of a giant cell tumour of distal radius using a vascularized pedicle graft of ulna. *J Hand Surg* 1998;23:742-7.
19. Wheeless C R. - The treatment of giant-cell tumors of the distal part of the radius. *Wheeless' Textbook of Orthopaedics*, 2014 (<http://www.wheelessonline.com>)
20. Cheng CY, Shih HN, Hsu KY, Hsu RW. Treatment of giant cell tumour of the distal radius. *Clin Orthop* 2001;383:221-8.