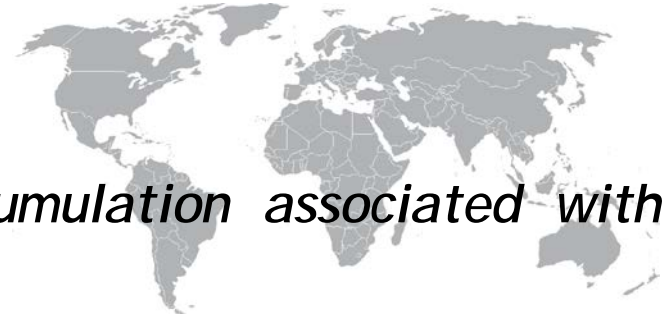



Bilateral perirenal fluid accumulation associated with tetralogy of fallot

Saim Sağ¹, Ömer Fatih Nas², Alper Öztürk¹, Dilek Yeşilbursa¹, Cüneyt Erdoğan²

ABSTRACT

This report describes a case of spontaneously developing bilateral perirenal fluid accumulation in a patient under monitoring for tetralogy of Fallot. The causal pathophysiology of perirenal fluid accumulation in patients with tetralogy of Fallot is unidentified. As a result of comprehensive examinations we establish that perirenal fluid develops due to high hematocrit. Perirenal fluid did not relapse after repeated phlebotomy treatment. Our case is the first to describe the combination of tetralogy of Fallot and perirenal fluid accumulation in the literature.

Keywords: perirenal fluid, tetralogy of fallot, polycythemia

INTRODUCTION

This report describes a case of spontaneously developing bilateral perirenal fluid accumulation in a patient under monitoring for tetralogy of Fallot. The underlying pathophysiology of perirenal fluid accumulation in patients with tetralogy of Fallot is unknown. Our case is the first to describe the combination of tetralogy of Fallot and perirenal fluid accumulation in the literature.

CASE REPORT

A 20-year-old patient diagnosed with tetralogy of Fallot and refusing the operation recommended presented to the emergency department in 2013 with widespread abdominal swelling and pain in the right leg. Tests performed on admission revealed urea 21 mg/dl, creatinine 0.84 mg/dl, GFR 100 ml/min/m², total protein 6.7 g/dl, albumin 3.4 g/dl, total cholesterol 190 mg/dl, HDL 41 mg/dl, LDL 134.2 mg/dl, AST 13 IU/L, ALT 7 IU/L, Na 138 mmol/L, K 4.42 mmol/L, Ca 9 mg/dl, WBC 6.07 K/ μ L, hemoglobin 19 g/dL, hematocrit 59%, MCV 86 fL, platelet count 280 K/ μ L, CRP 0.53 mg/dL, INR 3.5, sedimentation 10 mm/h and TSH 4.24 μ IU/ml. The patient had been using warfarin for 3 months for deep vein thrombosis. Abdominal CT was performed when ultrasound revealed bilateral retroperitoneal free fluid. At abdominal CT, both kidneys were of normal size but perirenal free fluid accumulation, 20 cm on the right and 14 on the left, was compressing the inferior vena cava and iliac veins (Figure 1). The patient's INR was 3.5 at time of admission, and we thought that these free fluids might be hematoma. The patient was hospitalized, and warfarin was stopped. At Doppler US of the lower extremity, we observed chronic thrombus extending from the bilateral main femoral veins to the iliac veins. The bilateral perirenal fluids had compressed the inferior vena cava. We decided to evacuate the fluids, whose formation we attributed to compression of the inferior vena cava by the deep vein thrombosis. When INR returned to normal, a catheter was inserted in the right and left perirenal space; 3000 ml serous fluid was drained from the right and 2000 ml from the left. At analysis of fluid from both sides, glucose was 89 mg/dl, total protein 0.82 g/dl, albumin 0.52 g/dl, LDH 77 IU/L, cholesterol

<7 mg/dl, triglyceride <7 mg/dl, Rivalta's test was negative, density was 1000, pH 8, urea 22 mg/dl, creatinine 0.57 mg/dl. Adenosine deaminase was negative, fluid was serous and culture tests were negative. Fluid specimens were described in terms of benign hypocellularity (a small number of cells and lymphocytes with degenerative changes) in pathology reports. We assessed that the collected perirenal fluids as a result of polycythemia developing secondary tetralogy of Fallot, and phlebotomy was performed to bring hematocrit to <45 g/dL. No fluid accumulation was observed after repeat phlebotomy, and the patient was restarted on warfarin and placed under monitoring.

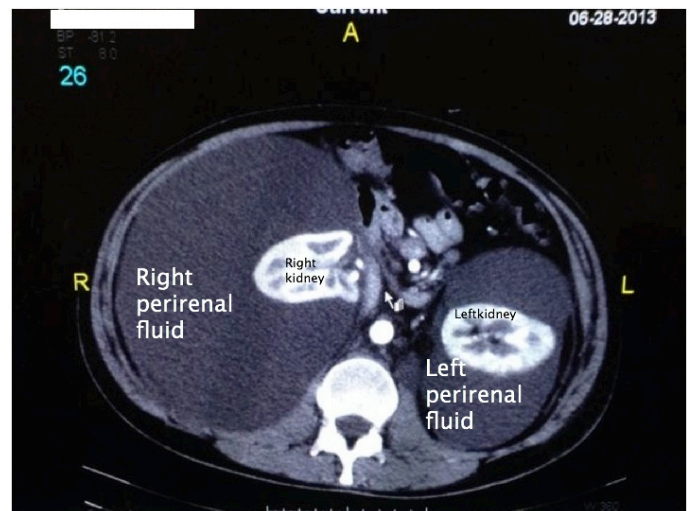


Figure 1: Contrast enhanced computed tomogram of the abdomen showing bilateral perinephric fluid collections, displacing normally functioning renal parenchyma within the capsule

¹ Department of Cardiology, Medical Faculty, Uludag University, Bursa, Turkey.

² Department of Radiology, Medical Faculty, Uludag University, Bursa, Turkey.

DISCUSSION

Perirenal fluid accumulation has been previously reported in Eisenmenger's syndrome and pulmonary hypertension (1, 2). These reports suggested that fluid might be associated with increased pulmonary arterial pressure affecting the renal venous system and fluid leakage from the superficial stellate veins into the subcapsular space. We rejected that hypothesis in our case since pulmonary hypertension did not develop due to pulmonary stenosis.

Examination of the literature revealed that perirenal fluid collection secondary to polycythemia was reported in four cases (3-6). Our patient seems to have a unique group of symptoms, not previously described in the literature. The underlying pathophysiology of perirenal fluid accumulation is unknown, though it has been postulated that polycythemia may play a causative role. As a result of extensive research, we thought

that perirenal fluid in our patient probably related with polycythemia. Hematocrit was reduced to normal levels by repeated phlebotomy treatment. The lack of fluid after repeated phlebotomy confirmed our thesis.

CONCLUSION

Bilateral perirenal fluid accumulation can be seen, albeit rare in patients with tetralogy of Fallot-related polycythemia. The pathophysiology underlying the perirenal fluid accumulation is not clear. Repeated phlebotomy to normalize hematocrit level may be used in the treatment of this condition. We hope that the description of these patients will lead to an understanding of their disease pathophysiology and treatment.

REFERENCES

1. Pölzl G, Lhotta K, Tiefenthaler M, Smekal A, Müller S. Bilateral perirenal fluid accumulation associated with Eisenmenger's syndrome. *Nephrol Dial Transplant*. 2004;19(7):1928-9.
2. Pentimone F, Meola M, Del Corso L. Bilateral perinephric fluid accumulation: an unusual manifestation of pulmonary hypertension--a case report. *Angiology*. 1993;44(6):500-5.
3. Viglietti D, Sverzut JM, Peraldi MN. Perirenal fluid collections and monoclonal gammopathy. *Nephrol Dial Transplant*. 2012;27(1):448-9.
4. Shaheen M, Hilgarth KA, Hawes D, Badve S, Antony AC. A Mexican man with 'too much blood'. *Lancet* 2003;362:806.
5. Burton IE, Sambrook P, McWilliam LJ. Secondary polycythaemia associated with bilateral renal lymphocoeles. *Postgrad Med J*. 1994;70(825):515-7.
6. Khan J, Sykes DB. Case report: a 37-year-old male with telangiectasias, polycythemia vera, perinephric fluid collections, and intrapulmonary shunting. *BMC Hematol*. 2014; 14:11.



<http://www.ejgm.org>