

A Pregnant Case with Severe Influenza A (H1N1) Virus Infection-Related ARDS

Turgut Teke¹, Ümme Duran¹, Emin Maden¹, Kazım Gezginç², Mehmet D Yavşan³, Kürşat Uzun¹

Selçuk University, Meram Medical Faculty,
Departments of Pulmonary Medicine¹ and
Obstetrics and Gynecology², Konya

³ Beyşehir State Hospital, Pulmonary Medi-
cine, Konya, Turkey

Eur J Gen Med 2011;8(2):163-7

Received: 08.07.2010

Accepted: 25.11.2010

ABSTRACT

Pregnant women are more susceptible to influenza and pregnancy may enhance the severity of the illness. In this article, we reported a 37-year-old pregnant woman with ARDS related to severe influenza A (H1N1) virus infection. A 37-year-old pregnant woman at 36 weeks gestation was admitted to our ICU with rapidly worsening dyspnoea. She had tachycardia, tachypnoea and severe hypoxia ($PaO_2/FiO_2=104$). A diagnosis severe H1N1 infection-related ARDS was made and treated with oseltamivir, broad-spectrum antibiotics, bronchodilators and NIV. Her nasopharyngeal swab was positive for H1N1. One day later, her hypoxia remained severe, and she was intubated and MV was commenced. Simultaneously, the patient gave birth to a healthy boy by emergency cesarean delivery. Her condition gradually improved. Pregnant women with severe H1N1 infection-related ARDS may be successfully treated with oseltamivir and mechanical ventilation.

Key words: Pregnancy, Influenza A (H1N1), Mechanical ventilation

Şiddetli İnfluenza A (H1N1)'ya Bağlı ARDS Gelişen Gebe

Gebe kadınlar gribe daha duyarlıdırlar ve hastalık bu kişilerde daha şiddetli olabilmektedir. Biz bu makalede şiddetli H1N1 enfeksiyonu nedeniyle ARDS gelişen 37 yaşında gebe bir hastayı sunduk. Otuz yedi yaşında 36 haftalık gebe bayan hasta YBÜ'mize hızla kötüleşen nefes darlığı şikâyeti ile yatırıldı. Yatışta taşikardisi, takipnesi ve şiddetli hipoksemisi ($PaO_2/FiO_2=104$) vardı. Hastaya H1N1 enfeksiyonu ile ilişkili ARDS tanısı konuldu. Oseltamivir, geniş spektrumlu antibiyotikler, bronkodilatörler ile birlikte NIV tedavisi başlandı. Nazofaringeal sürüntüsünde H1N1 pozitifliği. Bir gün sonra hipoksemisi daha da derinleşmesi üzerine hasta entübe edilerek MV'e bağlandı ve eş zamanlı olarak acil sezeryan operasyonuna verildi. Operasyonla sağlıklı bir erkek çocuğu doğurdu. Daha sonra hastanın klinik durumu hızla düzeldi. H1N1 enfeksiyonu nedeniyle ARDS gelişen gebe kadınlar oseltamivir ve mekanik ventilasyonla başarılı bir şekilde tedavi edilebilir.

Anahtar kelimeler: Gebelik, influenza A (H1N1), Mekanik ventilasyon

Correspondence: Dr. Turgut Teke
Selçuk Üniversitesi Meram Tıp Fakültesi
Göğüs Hastalıkları AD, 42080, Konya
Tel: 00903322236218
E-mail: turgutteke@hotmail.com

INTRODUCTION

Human infection with the influenza A virus (novel influenza A H1N1) was first reported in April 2009 and has since prompted the World Health Organization (WHO) to raise its pandemic alert to the highest level (1,2). The clinical pictures in severe cases of pandemic (H1N1) 2009 influenza affected were previously healthy young people (1). The risk of influenza complications is higher in some sub-populations. Pregnant women are an important medically susceptible subset of the population (3). During pregnancy both mother and baby are at increased risk when infected with either pandemic or seasonal influenza. Pregnancy may enhance the severity of the illness, thereby increasing mortality rates in this vulnerable population. The mechanical, immunological, and hormonal changes of pregnancy contribute to this heightened risk (4). In previous influenza pandemics, infected pregnant women had remarkably high rates of spontaneous abortion, preterm birth and maternal mortality (5,6). Moreover, pregnant women were more frequently hospitalized for cardiopulmonary events and for acute respiratory illness (7). Pregnant women were 4 times more likely to be hospitalized than the general public when infected with H1N1 influenza A virus (3). Nearly one-third of the pregnant women with confirmed novel H1N1 virus infection have been hospitalized during current H1N1 influenza A virus pandemic. Most of them had acute respiratory distress syndrome (ARDS) requiring mechanical ventilation (8). We report a 37-year-old pregnant woman with ARDS due to confirmed H1N1 virus infection and managed successfully with invasive mechanical ventilation.

CASE

A 37-year-old pregnant woman at 36 weeks of gestation was admitted to a regional hospital emergency department with a history of 4 days of fever, sore throat, headache, dry cough, nausea with vomiting, weakness, and myalgias. After intravenous rehydration, vitamin and acetaminophen medication, she was discharged home, but a few days later, her condition worsened. She was admitted to our ICU with rapidly worsening shortness of breath, productive cough, and hemoptysis. The patient had a history of asthma, but was not taking any asthma medications. On examination, she had tachycardia (128 beats/min), tachypnea (respiratory rate, 42 breaths/min), but no fever. Examination of the chest demonstrated rales and bronchophony in both lungs. The

chest radiograph and CT demonstrated bilateral alveolar opacities consistent with ARDS (Figure 1,3). Arterial blood gas analysis showed severe hypoxemia with metabolic acidosis with a $\text{PaO}_2/\text{FiO}_2$ score of 104. She had a normal white cell count (WCC) of $5.56 \times 10^3/\mu\text{L}$, but an elevated serum C-reactive protein (CRP) level of 70 mg/L. Also she had lymphopenia, hypoalbuminemia and elevated serum LDH. Bedside echocardiography was performed which revealed no evidence of global hypokinesia, all the chambers were normal, left ventricular ejection fraction was 60%. A diagnosis of ARDS related to severe H1N1 infection was made and treated with oseltamivir, broad-spectrum antibiotics, bronchodilators and noninvasive ventilation (NIV) with a FiO_2 of 1.0. Her nasopharyngeal swab was positive with polymerase chain reaction (PCR) test result for H1N1 influenza. One day later her hypoxia remained severe ($\text{PaO}_2/\text{FiO}_2$ score =70) under NIV, and she was intubated and MV was commenced with a FiO_2 of 1.0 and high-level PEEP (20 cmH_2O). She was given steroids for fetal lung immaturity and transferred to obstetric/neonatal department. Simultaneously, the patient gave birth to a healthy boy by emergency cesarean delivery. The patient had a MV secondary to an expanding pneumomediastinum and subcutaneous emphysema. Bacterial cultures of blood, urine and tracheal aspirate were negative. Her condition gradually improved. She was successfully weaned from ventilatory support on Day 7 and discharged home on Day 13. There was improvement in the radiographic findings on discharge (Figure 2,4).

DISCUSSION

Pregnancy has been a risk factor for increased illness and death for pandemic influenza. Pregnant women generally are at higher risk for influenza-associated morbidity and mortality compared with women who are not pregnant. The increased risk of complications is thought to be related to physiologic changes that occur during pregnancy (4). Several changes occur to the cardiovascular and respiratory systems, including increased heart rate, stroke volume, oxygen consumption, and decreased lung capacity during pregnancy (9). Relevant immunologic alterations also occur during pregnancy, with a shift away from cell-mediated immunity toward humoral immunity. These physiologic changes can render pregnant women more susceptible to, or more severely affected by, certain viral pathogens, including

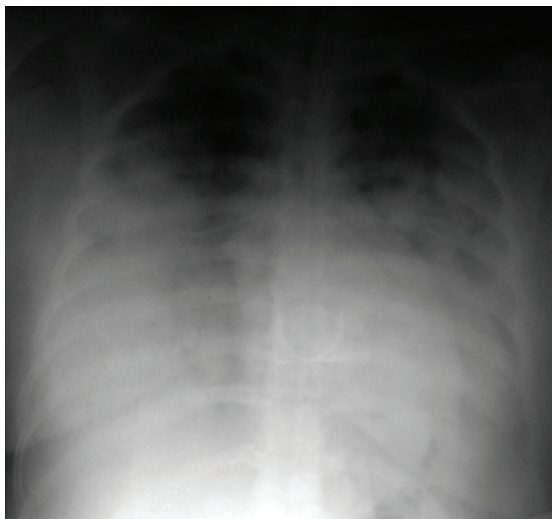

Figure 1. Chest radiograph in admission

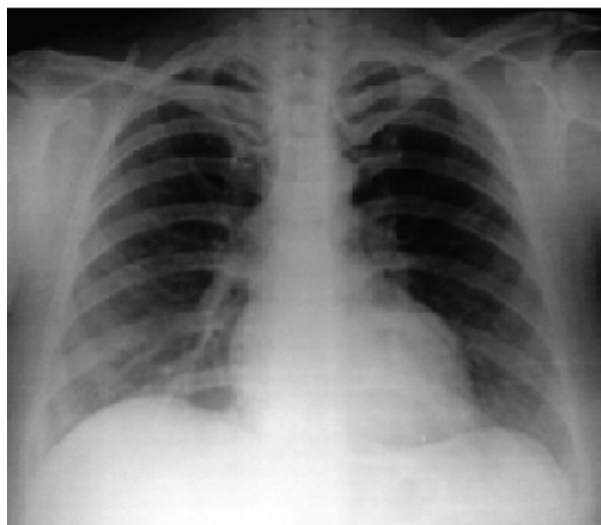


Figure 2. Chest radiograph on discharge

influenza (4).

Mortality rates among pregnant women in the pandemics of 1918 and 1957 appeared to be abnormally high (5,6). In recent influenza A (H1N1) pandemic, the rate of admission of pregnant women was four-times higher than in the general population with H1N1 infection. Six maternal deaths occurred among the 34 pregnant cases of H1N1 identified (3). During pregnancy, healthy women have a 4- to 5-fold increased rate of serious illness and hospitalization with influenza (10). Pregnant women were more frequently hospitalized for cardiopulmonary events and for acute respiratory illness (7,11). Nearly

one-third of the pregnant women with confirmed novel H1N1 virus infection have been hospitalized during the current pandemic. Most of them had severe respiratory distress (8). Wong et al. (12) reported an overall rate of intensive care unit admission of 50%, a rate for mechanical ventilation of 33%, and a rate for maternal death of 25%. In our patients we also intubated the patient and mechanical ventilation support was given to her with the diagnosis of ARDS due to progression of the disease and development of hypoxemic respiratory failure. The likelihood of sequelae increases with advancing gestational age; women at term are 5 times more likely to be

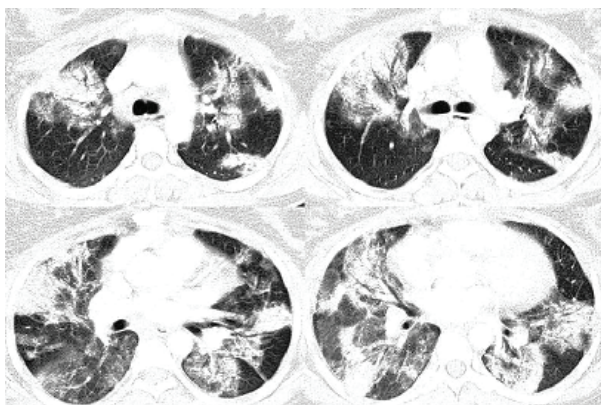


Figure 3. CT scan shows bilateral alveolar opacities

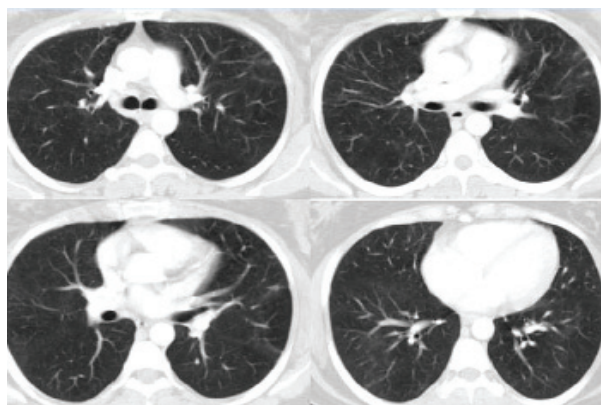


Figure 4. CT scan on control after four-week

hospitalized than postpartum women or those at lesser gestational ages (8). Our patient was also in the 36th week of the pregnancy, the third trimester.

Pregnant women with underlying medical conditions such as asthma are at particularly high risk for influenza-related complications (11). In pregnant women with no comorbidities, rate ratios for hospital admissions by trimester of pregnancy compared with the year before pregnancy are 1.7 for first, 2.1 for second, and 5.1 for third trimesters. The effects of pregnancy are greatest in women with one or more comorbidities, with rate ratios of 2.9, 3.4 and 7.9, respectively (11). There was mild asthma in our case, however she was not receiving any medicine.

During previous pandemics, infected pregnant women, particularly those with pneumonia, had remarkably high rates of spontaneous abortion and preterm birth (5,6). In a series of 5 pregnant women recently hospitalized for pandemic H1N1, the CDC reported that 2 women developed complications including spontaneous abortion (at 13 weeks) and premature rupture of membranes (at 35 weeks) (13). Much of the fetal morbidity was attributed to fetal hypoxia in mothers with severe ARDS and marked hypoxemia (14). After intubation and application of MV support, our patient gave birth to a healthy baby with emergent cesarean operation.

After birth the condition of the patient improved rapidly and in the 7th day she was weaned successfully from the MV support. The suggested criteria for early delivery are rapid maternal deterioration, failure to maintain adequate oxygenation, multiorgan failure, and difficulty with ventilation secondary to a gravid uterus (15). If the fetus is at a viable gestation and is at risk because of intractable maternal hypoxia, then there may be a benefit to the fetus in delivery. Any decision to administer steroids to promote fetal lung maturity should be made on an individual basis, in consultation with obstetrics and neonatology. Although cesarean section allows more rapid delivery in the critically ill patient, the increased physiologic stress of operative delivery may be associated with higher mortality in these patients (16).

The benefit of treatment with antiviral medications outweighs its theoretical risk because pregnant women are at increased risk for severe complications from the H1N1 virus infection. Therefore, early treatment with antiviral medication is recommended for pregnant women with suspected novel H1N1 infection regardless

of the gestational age (17). Oseltamivir has been used quite extensively in pregnancy with good results, and zanamivir, administered by inhalation, is increasingly a treatment option. These drugs are of most benefit when administered within 48 hrs of symptom onset and may reduce the incidence of pneumonia in patients with seasonal influenza (18). In a report of six maternal deaths with H1N1 pandemic influenza, none of these patients had received antivirals within 48 hrs of onset of symptoms (3). The oseltamivir treatment was initiated approximately 7 days of the beginning of symptoms due to deterioration of the general condition after admission to intensive care unit.

Our experience suggests that pregnant women, especially those in advancing gestational age, are at high risk of complications such as ARDS requiring mechanical ventilation from novel H1N1 influenza. Delivery of the pregnant patient with respiratory failure may be result in improvement in the mother's condition. Pregnant women with severe H1N1 infection-related ARDS may be successfully treated with oseltamivir and mechanical ventilation.

REFERENCES

1. Novel Swine-Origin Influenza A (H1N1) Virus Investigation Team. Emergence of a novel swine-origin influenza A (H1N1) virus in humans. *N Engl J Med* 2009;361:1-10.
2. Zarocostas J. World Health Organization declares A (H1N1) influenza pandemic. *BMJ* 2009;338: b2425.
3. Jamieson DJ, Honein MA, Rasmussen SA, et al. H1N1 2009 influenza virus infection during pregnancy in the USA. *Lancet* 2009;374:429-30.
4. Jamieson DJ, Theiler RN, Rasmussen SA. Emerging infections and pregnancy. *Emerg Infect Dis* 2006;12:1638-43.
5. Harris JW. Influenza occurring in pregnant women. *JAMA* 1919;72:978-80.
6. Freeman DW, Barno A. Deaths from Asian influenza associated with pregnancy. *Am J Obstet Gynecol* 1959;78:1172-5.
7. Neuzil KM, Reed GW, Mitchel EF, Simonsen L, Griffin MR. Impact of influenza on acute cardiopulmonary hospitalizations in pregnant women. *Am J Epidemiol* 1998;148:1094-102.
8. Satpathy HK, Lindsay M, Kawwass JF. Novel H1N1 virus infection and pregnancy. *Postgrad Med* 2009;121:106-12.
9. Goodnight WH, Soper DE. Pneumonia in pregnancy. *Crit Care Med* 2005;33:S390-7.
10. Mak TK, Mangtani P, Leese J, et al. Influenza vaccination in pregnancy: current evidence and selected national policies. *Lancet Infect Dis* 2008;8:44-52.

11. Dodds L, McNeil SA, Fell DB, et al. Impact of influenza exposure on rates of hospital admission and physician visits because of respiratory illness among pregnant women. *CMAJ* 2007;176:463-8.
12. Wong SF, Chow KM, Leung TN, et al. Pregnancy and perinatal outcomes of women with severe acute respiratory syndrome. *Am J Obstet Gynecol* 2004;191:292-7.
13. Carlson A, Thung SF, Norwitz ER. H1N1 Influenza in Pregnancy: What All Obstetric Care Providers Ought to Know. *Rev Obstet Gynecol* 2009;2:139-45.
14. Lapinsky SE. H1N1 novel influenza A in pregnant and immunocompromised patients. *Crit Care Med* 2010;38(4 Suppl):52-7.
15. Tomlinson MW, Caruthers TJ, Whitty JE, Gonik B. Does delivery improve maternal condition in the respiratory-compromised gravida? *Obstet Gynecol* 1998;91:108-11.
16. Jenkins TM, Troiano NH, Graves CR, Baird SM, Boehm FH. Mechanical ventilation in an obstetric population: Characteristics and delivery rates. *Am J Obstet Gynecol* 2003;188:549-52.
17. Rasmussen SA, Jamieson DJ, Macfarlane K, et al. Pandemic influenza and pregnant women: summary of a meeting of experts. *Am J Public Health* 2009;99 (suppl 2): S248-54.
18. Tanaka T, Nakajima K, Murashima A, Garcia-Bournissen F, Koren G, Ito S. Safety of neuraminidase inhibitors against novel influenza A (H1N1) in pregnant and breastfeeding women. *CMAJ* 2009;181:55-8.